

## ABSTRACT

## Efficiency of CBCT for assessment of impacted mandibular third molars

A radiographic examination of mandibular third molars is meant to support the surgeon in establishing a treatment plan. For years panoramic (PAN) imaging has been the first choice method; however, where an overprojection is observed between the third molar and the mandibular canal and when specific signs suggest a close contact between the molar and the canal, cone beam computed tomography (CBCT) may be indicated. The present review provides an evaluation of the efficacy of CBCT for assessment of mandibular third molars using a six-tiered hierarchical model by Fryback and Thornbury (1991). Levels 1-3 include studies on low evidence levels mainly regarding the technical capabilities of a radiographic method and the diagnostic accuracy of the related images. Levels 4-6 include studies on a higher level of evidence and assess the diagnostic impact of a radiographic method on the treatment of the patient in addition with the outcome for the patient and society including cost calculations.

Only very few high-evidence studies on the efficacy of CBCT for radiographic examination of mandibular third molars exist and in conclusion, periapical or PAN examination is sufficient in most cases before removal of mandibular third molars, but CBCT may be suggested when one or more signs for a close contact between the tooth and the canal are present in the 2D image - if it is believed that CBCT will change the treatment or the treatment outcome for the patient. Further research on high-evidence levels is needed.

Denne artikel er oprindeligt publiceret i: *Dentomaxillofacial Radiology* 2015;44:20140189 (CBCT Special Issue).

# Efficacy of cone beam computed tomography for assessment of impacted mandibular third molars: a review based on a hierarchical model of evidence

Louise Hauge Matzen, adjunct, ph.d., Section of Oral Radiology, Department of Dentistry, Aarhus University

Ann Wenzel, professor, dr.odont. ph.d., Section of Oral Radiology, Department of Dentistry, Aarhus University

**R**adiographic examination precedes removal of a mandibular third molar. The radiographic image contributes to the treatment plan, herein the decision for removal of the tooth. Ideally, the radiographic examination of mandibular third molars should provide information about the tooth itself, the surrounding bone, the neighboring tooth and related anatomical structures. Parameters that should be assessed are state of impaction, root development, angulation of the tooth, number of roots, root morphology, related pathology and most important, the relation between the tooth/roots and the mandibular canal, and a sufficient image should display the whole third molar and the mandibular canal in the region.

The use of radiography aims to reduce postoperative complications. These can be pain, swelling, excessive bleeding, infection and reduced mouth opening (1,2); however, sensory disturbances to the nerves, i.e. the alveolar inferior nerve (IAN),

the buccal nerve and the lingual nerve is seen as the most severe postoperative complications after removal of a mandibular third molar (3-6). In a radiographic image of the third molar region, only the course of the IAN may be estimated since the mandibular canal, within which

### EMNEORD

Molar, third; radiography; cone beam computed tomography

the nerve is situated, is usually visible. The course of the other two essential nerves in the region is not seen in radiographs.

### Conventional radiographic methods

An intraoral image may be sufficient before surgical intervention of mandibular third molars, if the whole tooth and the mandibular canal are displayed in the image. If there is an overprojection between the roots of the tooth and the canal, eccentric examinations can be performed and the tube shift technique in the vertical plane (SLOB rule (same lingual opposite buccal)) (7) used to interpret, if the third molar is positioned buccally or lingually to the mandibular canal (8-12). Moreover, an axial/occlusal examination in combination with the eccentric examinations to support the information on the bucco-lingual inclination of the third molar has been suggested (10-12). In general the sharpness of the intraoral image is higher than that of the panoramic (PAN) image, and the magnification factor when using the paralleling technique is around 1.05 with no image distortion (13).

There may however be problems with positioning the intraoral receptor (14), which may be further accentuated when digital receptors replace the conventional film. Particularly solid state sensors may be uncomfortable to the patient since they are much thicker than film and in most cases a wire connects the sensor with the computer (15). If the patient perceives more discomfort when digital receptors are used, it might be speculated that the number of retakes will also increase, and that it may be just impossible to display the mandibular third molar region in an intraoral image. One study compared periapical imaging with solid state sensors, storage phosphor plate systems and film for examination of a mandibular third molar (14) and concluded that up to 38% were insufficient according to criteria for a sufficient image, and after a retake using conventional film, still 22% were insufficient.

Owing to the difficulties in positioning the intraoral receptor for periapical exposures, recommendations suggest that PAN radiography may be the method of choice before removal of mandibular third molars (16). A PAN examination is readily performed with little or no discomfort to the patient in opposition to intraoral radiography. Moreover, it is a relatively low dose examination, which provides an image of all four third molars in one exposure comparable to between two and 16 intraoral exposures (17), and more recent equipment can even provide segmented images exposing and displaying only the molar region(s) in question. Thus, PAN radiography will often be the first choice method for evaluation of mandibular third molars where such units are available.

In a PAN image it may firstly be interpreted whether there is overprojection of the roots of the tooth and the mandibular canal. Secondly, when an overprojection is observed, seven signs in the PAN image have been suggested to indicate a close contact between the roots of the third molar and the neurovascular bundle in the mandibular canal (18). However, the signs seem

not to be equally reliable. In a recent review it was concluded that three of the signs (interruption of the radiopaque borders of the canal, diversion of the canal and darkening of the roots) were more valid to predict a close contact than the remaining four. It was concluded that absence of these signs could not fully ensure no close contact (19,20). This means that when the roots overproject the mandibular canal in the PAN image, and in particular if one or more of the signs are present, further radiographic examination may be suggested.

Stereo-scanography (SCAN) has been known since the 1990s (21). The SCAN consists of four images obtained in one examination, which display the third molar region in one orthogonal and one disto-eccentric projection and two projections cranial to these, organized in the SCAN image below the first two exposures. In both directions the tube shift angle is 4° (22). In SCAN the relation between the roots of the third molar and the mandibular canal can be determined by using the tube shift technique or viewing with stereopsis (22,23). Only few units on the market provide the possibility for SCAN, and the technique has not gained wide spread attention.

The posterior-anterior projection (PA) of the skull may add value in determining the relationship between the roots of the third molar and the mandibular canal in addition to the angulation of the tooth and roots in the bucco-lingual plane. The bucco-lingual relation between the mandibular third molar and the mandibular canal may thus be interpreted (24,25). This projection demands that a cephalostat or another type of unit for examination of the skull is available in the clinic. Moreover, there is often overlapping structures of the jaw in the mandibular molar region, which may impede a clear view of the third molar.

The conventional tomographic technique may also add information in the determination of the bucco-lingual relationship between the tooth/root and the mandibular canal. This technique displays pre-determined thin slices of a selected region of the jaw. During the radiographic examination the tube and film simultaneously move in opposite directions around a fixed axis, which is located in the focal plane (26).

### Cone Beam CT scanning

Cone Beam computed tomography (CBCT) scanning is a refinement or simplification of the medical CT scanning made for dentistry and related disciplines. The main difference between CT and CBCT is that CBCT uses a cone-shaped or rectangular-shaped instead of a fan-shaped x-ray beam, and moreover this technique often uses a flat panel x-ray detector instead of one or several rows of detectors (27). One single rotation is thus performed to collect the data needed to reconstruct the examined tissue volume; this increases the spatial resolution of the image sections and in most instances lowers the dose to the patient compared to a medical CT examination (27,28). Consequently, CBCT has in most cases taken over the role of medical CT in dentistry. The radiation dose for an examination of a mandibular third molars is higher for medical CT scanning

compared with PAN imaging, PA and SCAN (29), and although CBCT might provide lower radiation doses to the patient than medical CT, the dose is still higher for most CBCT units than for PAN imaging etc. (28,30,31).

Apart from the parameters that influence the quality of 2D images such as the examined object, tube voltage, amperage and spatial resolution, the image quality of CBCT images is also influenced by the scanned tissue volume, the so-called field-of-view (FOV) and the resolution defined by the voxel size (32,33). The size of a voxel is defined by its height, width and depth. The spatial resolution (number of voxels) is defined in the unit, and for each FOV more than one resolution may be offered. It differs between units how many FOVs are available, but minimizing the FOV often reduces patient dose and improves image quality because of reduced scattered radiation (27).

Since CBCT images can display the examined volume in all anatomical planes, and the examiner is able to scroll through the sub-millimeter image slices, it may be assumed that more detailed information is offered than in 2D imaging. When an overprojection of the mandibular canal by the roots of the third molars is seen in the traditional 2D images, it is expected that CBCT can reveal the exact relationship between the third molar and the mandibular canal in cross-sectional image sections (34). If no bony separation is observed between the third molar and the mandibular canal in the CBCT images, this may be interpreted as a direct contact between the structures. Moreover, it is possible to assess root flex in the bucco-lingual plane.

#### Protocols including CBCT before surgical intervention of mandibular third molars

The use of CBCT has been discussed, and recently published guidelines (17) conclude that where conventional radiographs suggest a direct inter-relationship between a mandibular third molar and the mandibular canal, and when a decision to perform surgical removal has been made, CBCT may be indicated. The guidelines indicate that a conventional radiographic method should precede CBCT for this task. As also concluded in the report, the guidelines are extracted based on studies on a rather low level of evidence, therefore, more research is needed on the efficacy of CBCT.

Combinations of radiographic methods have been suggested as clinical "protocols" for an examination of a lower third molar before surgical intervention. A published review on preoperative imaging procedures for mandibular third molars suggested a strategy for radiological examination before surgical removal: 1) PAN and/or intraoral imaging was first choice and sufficient in the majority of cases when there was no overprojection between the roots of the third molar and the mandibular canal; 2) A PA was a supplement to the PAN and/or intraoral images, if the interpretation of the relation between the roots of the tooth and the mandibular canal was not unequivocal; and 3) CBCT or low-dose CT was used when the above mentioned examinations were still not adequate (24). Recently, another

#### Hierarchical model of evidence

Level 1	Technical quality of the imaging method, i.e. resolution, sharpness, and gray scale
Level 2	Effect on diagnostic accuracy, i.e. evaluation of the sensitivity, specificity and other accuracy parameters of a new method (usually in ex vivo studies)
Level 3	Effect on the dentist's diagnostic thinking, i.e. changes in diagnosis using a new diagnostic method in relation to a previous (well known) method (usually as paper clinics or questionnaire studies)
Level 4	Effect on the dentist's choice of treatment, i.e. change of treatment strategy using a new diagnostic method in relation to a previous (well known) method (usually in clinical studies in which treatment choice is decided with and without the new diagnostic method and treatment is effected)
Level 5	Effect on patient's treatment outcome, i.e. changes in treatment quality, postoperative complications, or treatment prognosis based on the new diagnostic method (usually in Randomized Clinical Trials between the new and a previous (well known) diagnostic method)
Level 6	Effect on societal costs, i.e. the economic impact of using a new diagnostic method for the patient and society. The societal costs and, for radiographic methods dose, are weighed against benefits of a diagnostic method (usually as part of prospective clinical studies and Randomized Clinical Trials)

**Table 1.** Fryback & Thornbury's (1991) (36) hierarchical classification system for evaluating the diagnostic efficacy of imaging methods (abbreviated and exemplified).

**Table 1.** Fryback & Thornbury's (1991) (36) model til evaluering af evidensen for anvendelsen af en billeddannende metode (forkortet og eksemplificeret).

preoperative imaging protocol has been evaluated, which had been implemented over a five-year period, and in which SCAN was applied instead of the PA projection (35). By both suggested protocols, a PAN image would suffice in approximately 50%, and in 23/24% of the cases the third molars received a 3D examination before surgical intervention (24,35). None of these protocols have however been validated or compared to a different protocol of the same population, thus the evidence for the protocols is sparse.

#### Evidence levels for evaluation of a new imaging method

Fryback and Thornbury (36) have introduced a six-tiered hierarchical model of efficacy of diagnostic imaging (Table 1).

### Studies using a “gold standard” for evaluating the relationship to the mandibular canal

Study	Radiographic method	Sample of third molars	Radiographic signs of close/direct contact	Results
Tantanapornkul et al. 2007 (42)	PAN vs. CBCT	142	PAN: int, dark, div, ron CBCT: no bony separation	PAN: sens 0.70; spec 0.63 CBCT: sens 0.93; spec 0.77
Ghaemini et al. 2009 (43)	PAN vs. CBCT	53	PAN: int, dark, div, defl, ron, can CBCT: no bony separation	PAN: sens 1.0; spec 0.03 CBCT: sens 0.96; spec 0.23
Suomalainen et al. 2010 (40)	SCAN vs. CBCT	18	SCAN: same level in SLOB/ste-reovision CBCT: no bony separation	No exact figures available
Matzen et al. 2013 (41)	PAN vs. SCAN vs. CBCT	147	PAN: int, div, dark SCAN: same level in SLOB/ste-reovision CBCT: no bony separation	PAN: sens 0.29; spec 0.78 SCAN: 0.57; spec 0.53 CBCT: sens 0.67; spec 0.68

**Table 2.** Studies evaluating the diagnostic accuracy of CBCT for assessment of the relation between the mandibular third molar and the mandibular canal using a clinical “gold standard”. Abbreviations: dark: darkening of the roots; int: interruption of the radiopaque borders of the canal; div: diversion of the canal; defl: deflection of the roots; can: narrowing of the canal; ron: narrowing of the roots; sens: sensitivity; spec: specificity; PAN: panoramic imaging; SCAN: scenography; SLOB, same lingual opposite buccal.

**Table 2.** Oversigt over studier, der har evalueret den diagnostiske rigtighed af CBCT ved hjælp af en klinisk “gold standard” til vurdering af relationen mellem mandibulære visdomstænder og canalis mandibulae. Forkortelser: dark: mørkning af rødder; int: afbrudt kanalforløb; div: afbøjning af kanalen; defl: afbøjning af rødderne; can: indsnævring af kanalen; ron: indsnævring af rødderne; sens: sensitivitet, spec: specificitet; PAN: panoramaoptagelse; SCAN: scanografi; SLOB: same lingual opposite buccal.

They stated that a localized view of the goal of diagnostic radiology should be to provide the best images and the most accurate diagnoses possible. But a more global analysis reveals diagnostic radiology to be part of a larger system with the goal to treat patients effectively and efficiently (36). The model includes studies at 6 levels, and the evidence increases with each level.

Studies on level 1 evaluate the basic, physical parameters describing technical image quality in an imaging system such as sharpness, brightness, contrast and presence of artifacts; for example the general influence of change in kV, mA, focal area and focus-film distance for image quality has been described in textbooks (37). Studies on level 2 evaluate the performance of the imaging system for the purpose of establishing a diagnosis, and it requires interpretation of the image by an observer. One of the main features is the need for a validation (“gold standard”) that the radiographic findings can be held against. Studies on levels 3 and 4 evaluate whether the use of the image modality gives rise to a change in diagnostic thinking or patient management. Studies on level 5 evaluate whether the radiographic examination changes the health of the patient while level six evaluates costs of an examination against its expected benefits as a rational guide for the clinician’s decision on whether or not to subscribe the examination. The design for a study to obtain evidence on this level is the randomized controlled trial (RCT). Studies on level 6 further evaluate resource allocations for large groups and assess how the use of resources may provide medical benefits to society. The optimal design for a study to

obtain evidence on this level is a full cost-effectiveness study as performed in so-called Health Technology Assessments (HTA).

In the following, studies on levels 2-6 are described where CBCT, either solely or in comparison with other radiographic techniques, has been used in the assessment of mandibular third molars.

#### Level 2 – Effect on diagnostic accuracy

##### Surgical validation for radiographic findings in assessment of mandibular third molars

To assess the diagnostic accuracy of a radiographic modality, a validation method or reference standard is mandatory in order to compare the radiographic findings with the “true” situation. For mandibular third molars the convention has been to validate the radiographic observations against the intra- and post-operative clinical findings, which is easily performed for the basic tooth-related parameters: state of impaction and number and morphology of the roots. On the other hand, a validation for the relation between the roots and the mandibular canal/ IAN has been discussed. In a recent review based on five studies assessing the seven signs for a close contact between the roots of the molar and the mandibular canal in a PAN image, sensory disturbance was used as the reference standard in three of the studies, while IAN exposure observed after removal of the tooth was used as the true expression for a close contact in two studies (19). Both validation methods were stated in the review as adequate reference standards for a close relation to the man-

dibular canal (19,20). A third clinical sign for direct contact to the IAN is grooves in the root complex from the IAN, which has also been used in some studies (23,38-41).

#### Accuracy of CBCT with a reference standard

The diagnostic accuracy of CBCT using a reference standard has generally been sparsely examined. One study concluded that

CBCT was more reliable than PAN imaging for evaluation of number of roots (40), and a recent study compared three methods: PAN imaging, SCAN and CBCT and found that the modalities seemed equally valuable for examination of tooth angulation, number and morphology of roots of mandibular third molars (41). However, CBCT was found to be superior to SCAN for assessing root flex in the bucco-lingual direction (coronal plane).

### Studies using CBCT as reference standard for evaluating the relationship to the mandibular canal

Study	Radiographic method	Sample of third molars	Radiographic signs of close/direct contact	Results
Nakagawa et al. 2007 (45)	PAN vs. CBCT	73	PAN: int CBCT: no bony separation	Agreement 64.3%
Tantanapornkul et al. 2009 (46)	PAN vs. CBCT	253	PAN: dark CBCT: 1)grooving of the roots; 2)cortical thinning or no bony separation	Agreement: 1)62 %; 2)72% sens: 1)0.31; 2)0.80 spec: 1)0.76; 2)0.68
Kositbowornchai et al. 2010 (47)	1)PAN + an intraoral or 2) two eccentric intraorals vs. CBCT	32	1)Bucco-lingual relation using SLOB 2)Bucco-lingual relation using SLOB CBCT: bucco-lingual relation	sens: 1)0.98 2)0.84 spec: 1)0.17; 2)0.44
Dalili et al. 2011 (48)	PAN vs. CBCT	43	PAN: overprojection, can, div, int, dark CBCT: no bony separation reovision	Agreement: overprojection 66.7%; can 27.3%; div 24.2%; int: 30.3%; dark 15.2%
Jung et al. 2012 (49)	PAN vs. CBCT	175	PAN: int, dark + int CBCT: no bony separation	Agreement: int 28.4% dark + int 47.1%
Neves et al. 2012 (50)	PAN vs. CBCT	75	PAN: dark, div, can, int, int + dark CBCT: no bony separation	Agreement: dark 37.4%; div 7.8%; can 2.0%; int 33.3%; int + dark 10.0%
Harada et al. 2013 (51)	PAN vs. CBCT	307	PAN: dark, defl, ron, dab, int, div, can	Agreement: dark 38.1%; int 50.6%; can 11.3%
Shahidi et al. 2013 (52)	PAN vs. CBCT	132	PAN: int, dark, div, defl CBCT: no bony separation	int: sens 0.79; spec 0.60 dark: sens 0.55; spec 0.80 div: sens 0.24; spec 0.80 defl: sens 0.57; spec 0.80
Sekerci et al. 2014 (53)	PAN vs. CBCT	781	PAN: int, dark, dev, can, ron, div	Agreement: int 26.2%; dark 43.4%; dev 16.4%; can 6.6%; ron 5.0%; div 2.5%
Matzen et al. 2014 (35)	PAN/ SCAN vs. CBCT		PAN: int, can, div SCAN: same level in SLOB/ste-reovision CBCT: no bony separation	Agreement: int and/or can and/or div 53% same level 76%

**Table 3.** Studies evaluating the diagnostic accuracy of CBCT for assessment of the relation between the mandibular third molar and the mandibular canal using CBCT as the reference standard. Agreement: correlation between the methods. Abbreviations: dark: darkening of the roots; int: interruption of the radiopaque borders of the canal; div: diversion of the canal; defl: deflection of the roots; can: narrowing of the canal; ron: narrowing of the roots; dab: dark or bifid root; sens: sensitivity; spec: specificity; PAN: panoramic imaging; SCAN: scenography; SLOB, same lingual opposite buccal.

**Table 3.** Oversigt over studier der har evalueret den diagnostiske rigtighed af CBCT til vurdering af relationen mellem mandibulære visdomstænder og canalis mandibulae, og hvor CBCT er anvendt som "gold standard". Forkortelser: dark: mørkning af rødder; int: afbrudt kanalforløb; div: afbøjning af kanalen; defl: afbøjning af rødderne; can: indsnævring af kanalen; ron: indsnævring af rødderne; dab: mørke og bifide rødder; sens: sensitivitet, spec: specificitet; PAN: panoramaoptagelse; SCAN: scanografi; SLOB: same lingual opposite buccal.



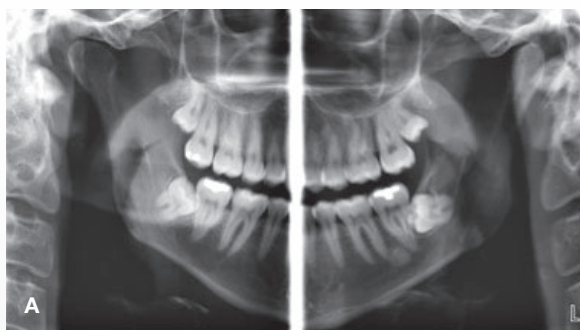
Table 2 shows an overview of studies on diagnostic accuracy assessing the relation between the third molar and the mandibular canal using a reference standard. In a recent review, Guerrero and coworkers (44) included two studies on diagnostic accuracy of CBCT using a gold standard. One study found that CBCT was significantly superior to PAN images in predicting neurovascular bundle exposure during removal of the third molar (42). By contrast, the other study concluded that CBCT was not more accurate than PAN images in predicting IAN exposure (43). Furthermore, one study has compared SCAN and CBCT (40), and another study three methods: PAN imaging, SCAN and CBCT, for assessment of the relation between the roots of the mandibular third molar and the mandibular canal (41). In one study it was concluded that CBCT was more reliable than SCAN for determining this relation (40) while the other demonstrated that CBCT was not significantly different from SCAN, but more accurate than PAN images to identify a direct contact to the mandibular canal (no bony separation between the tooth and canal) (41). In conclusion, it seems that CBCT is more accurate to display a direct contact between these structures than 2D radiographic methods.

#### Comparison between other radiographic methods and CBCT without a reference standard

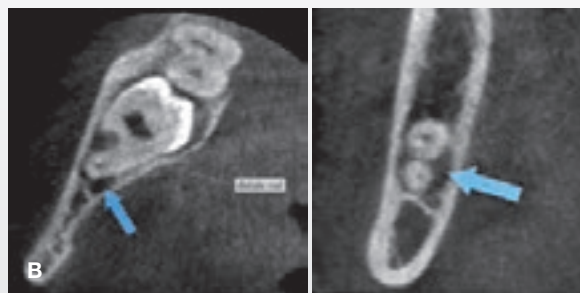
Studies have examined the correlation between the relation bet-

ween the third molar and the mandibular canal in PAN images and CBCT images (Table 3). A pilot study assessed the ability of 1) a PAN image in combination with an angled,  $-20^\circ$ , periapical image and 2) two periapical images taken at  $0^\circ$  and  $-20^\circ$  to identify a direct contact between the mandibular third molar and the mandibular canal using CBCT as the reference (47). It was concluded that both methods had high potential for determining a direct contact between the tooth and the mandibular canal (47). In another study it was found that darkening of the roots of the third molar seen in PAN images was correlated with thinning or perforation of the lingual cortical bone by the roots rather than grooving of the roots seen in the CBCT image sections (46). More studies have examined different signs for a direct contact seen in PAN images with a direct contact seen in CBCT. In some studies it was found that interruption of the radiopaque borders of the canal in PAN images predicted a direct contact between the roots of the third molar and the mandibular canal observed in CBCT (45,49-52), (Fig. 1) and in other studies it was found that darkening of the roots in PAN images predicted a direct contact between the roots of the third molar and the mandibular canal observed in CBCT (48,50,52,53). In one of the studies darkening of the roots was present in 5 of 43 of the PAN images and absence of cortication between the third molar and the mandibular canal was present in 33 of 43 of CBCT images (48). The 5 cases were interpreted with no bony separation

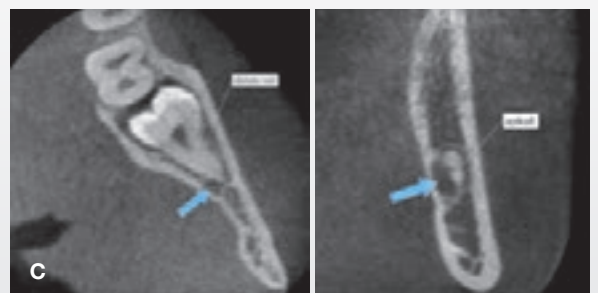#### Relationship between interruption of the white line borders seen in a panoramic image and no bony separation seen in CBCT



**Fig. 1. A.** Segmented panoramic image of the two mandibular third molars. Interruption of the upper radiopaque borders of the canal is present in both sides. **B.** Axial and coronal views of the right mandibular third molar showing no bony separation between the roots of the third molar and the mandibular canal. Arrows indicate the mandibular canal. **C.** Axial and coronal views of the left mandibular third molar showing no bony separation between the roots of the third molar and the mandibular canal. Arrows indicate the mandibular canal.



**Fig. 1. A.** Reduceret panoramabilleder af to mandibulære visdomstænder. Afbrudt kanalforløb er til stede i begge sider. **B.** Aksialt og koronalt snit af den højre mandibulære visdomstand hvor der ikke ses knogleseparation mellem visdomstandens rødder og canalis mandibulae. Pile viser canalis mandibulae. **C.** Aksialt og koronalt snit af den venstre mandibulære visdomstand hvor der ikke ses knogleseparation mellem visdomstandens rødder og canalis mandibulae. Pile viser canalis mandibulae.



in the CBCT images, on the other hand, 28 cases were also determined with no bony separation in the CBCT images, and therefore, the agreement between the presence of darkening of the roots in the PAN images and absence of bone between the tooth and the mandibular canal was only 15.2% (48). Recently, in one study it was found that if interruption of the radiopaque borders of the canal and/or diversion of the canal and/or narrowing of the lumen of the canal was present in the PAN images, there was 1.6 times the probability that a direct contact was seen in the CBCT (35). In summary, it seems that more of the seven signs for close contact to the mandibular canal seen in PAN images are associated with a direct contact between the tooth and the mandibular canal observed in CBCT, but the absence of these signs do not indicate that a direct contact does not exist.

A recent study showed that the inter-observer reproducibility for assessing the variable “direct contact” between tooth and canal in CBCT sections was excellent for two trained radiologists, while overall the mean for observer concordance ranged from 60-95 percent (54). There was no significant difference between observer concordance for two CBCT units under evaluation except for assessing root flex in the mesio-distal direction (sagittal plane), for which observer concordance was higher for Scanora3D (Soredex, Helsinki, Finland). The authors suggested that even though CBCT does not validate the anatomic position of the inferior alveolar nerve, but displays merely the mandibular canal, it has been shown that when the nerve was visible during surgery, a direct contact between the tooth and the mandibular canal was often demonstrated in the CBCT sections, and the diagnostic ac-

curacy for this variable was higher for CBCT than for other radiographic methods (41,42). CBCT may thus be suggested as a surrogate reference standard to demonstrate this relationship when other modalities are evaluated.

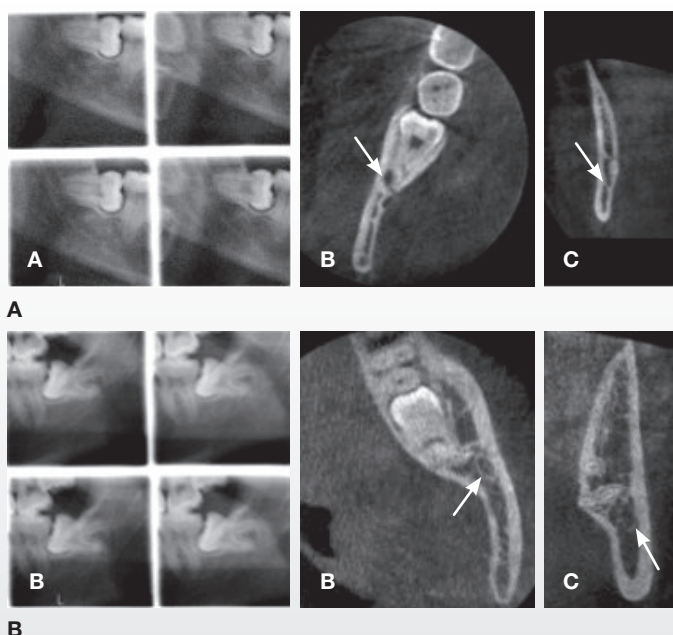
### Level 3 – Effect on diagnostic thinking

Even with the knowledge that CBCT may be more accurate in displaying the relationship between the tooth and the mandibular canal than 2D methods, the decision making process must be assessed to explore whether the information from CBCT changes the surgeon’s diagnostic thinking, i.e. treatment planning. It may be that implementing CBCT does nothing more than reassure the clinician and maintain the established treatment of the patient. Only one pilot study on level 3 seems to be available, which assessed the differences between a treatment plan established on the basis of PAN images and on CBCT (55). It was concluded that CBCT contributed to “optimal” risk assessment and as a consequence, to more adequate surgical planning. The observers reclassified more subjects to a lower risk for IAN injury after the CBCT images were available, which also resulted in a significant difference in the suggested surgical approach. The treatment was not carried out though; therefore no data on the actual treatment or treatment outcome was available.

### Level 4 – Effect on choice of treatment

Recently it has been recommended to perform coronectomy, where only the crown of the tooth is removed and the root com-

## Examples of cases changing treatment according to findings seen in CBCT



**Fig. 2. A.** Example of a right mandibular third molar for which the treatment was changed from surgical removal to coronectomy after CBCT images were available. A: stereo-scanogram; B: CBCT axial view; C: CBCT coronal view. Arrows indicate the mandibular canal. **B.** Example of a left mandibular third molar for which the treatment was changed from coronectomy to surgical removal after CBCT images were available. A: stereo-scanogram; B: CBCT axial view; C: CBCT coronal view. Arrows indicate the mandibular canal.

**Fig. 2. A.** Eksempel på en mandibulær visdomstand i højre side, hvor behandlingen blev ændret fra amotio til koronektomi, efter CBCT-billeder var til rådighed. A: stereo-scannogram; B: CBCT-snit i aksialplanet; C: CBCT-snit i koronalplanet. Pile viser canalis mandibulae. **B.** Eksempel på en mandibulær visdomstand i venstre side, hvor behandlingen blev ændret fra koronektomi til amotio, efter CBCT-billeder var til rådighed. A: stereo-scannogram; B: CBCT-snit i aksialplanet; C: CBCT-snit i koronalplanet. Pile viser canalis mandibulae.

plex left in the bone, in order to avoid injury to the IAN (56-61). In one of the first studies on coronectomy of mandibular third molars it was concluded that partial removal of the tooth may be considered as an alternative method of mandibular third molar surgery in cases where complications may be expected if the full tooth is removed (62). Subsequently, an RCT was published comparing the incidence of injury to the IAN as a result of either coronectomy or full removal of the mandibular third molar (57). It was found that there was no incidence of injury to the IAN in the coronectomy group (57), and this finding has been supported in several studies for the past five years (58-61). Moreover, there was no significant difference in the frequency of "dry socket" between the tooth removal and coronectomy group (57); this was confirmed in another randomized controlled trial, which in addition found that patients reported more pain one week post-operatively after removal of the third molar than after coronectomy (59). It seems therefore that coronectomy is a method to avoid injury to the IAN, but data are missing on the long-term fate of the remaining root complex and on patient-related outcomes such as pain and swelling during and after the intervention.

Only one study seems to have assessed the influence of CBCT on the actual treatment of mandibular third molars, and the study also identified radiographic factors with an impact on deciding on coronectomy versus full tooth removal (63). The first treatment plan was established on the basis of PAN images and SCAN. Thereafter, CBCT was available and a second treatment plan was established, by which the treatment was performed. The treatment plan changed in 12% of the cases; 15 teeth changed from full removal to coronectomy and in 7 cases, it was the opposite (examples in Fig. 2). Logistic regression analysed factors predisposing for the decision: coronectomy, and the most important factor for this change was that no bone separation between the third molar and the mandibular canal was seen in CBCT images. This finding was a necessary, but not alone a sufficient sign in CBCT to decide on coronectomy, and other signs were narrowing of the canal lumen and that the canal was positioned in a root flex.

#### Level 5 - Effect on patient's treatment outcome

The most severe patient-related outcome after third molar surgery may be sensory disturbances, particularly permanent injuries to the IAN, but other parameters could also be evaluated. Several post-operative complications have been reported after surgical intervention such as excessive bleeding, trismus, swelling, dry socket and infection (1,2). Changes in sensory feeling have been reported in pro- and retrospective cohort studies to occur with a frequency of 0.6-6% for temporary disturbances and 0.4-1% for permanent disturbances (3-6,35).

The optimal study design to obtain evidence on the impact of CBCT on patient outcome compared with for example, PAN imaging is the RCT, in which patients after inclusion in the study are randomized by lot to an experimental (CBCT) or a control (e.g.

PAN) group. Two RCTs seem to have been conducted on the use of CBCT versus PAN imaging for estimating patients' treatment outcome with regard to sensory disturbances in the innervation area of the IAN. One study found that in 256 operated patients, two in the CBCT group and five in the PAN imaging group experienced permanent sensory disturbances to the IAN (64). Moreover, in an ongoing study, preliminary results were that 17 of 116 operated patients had temporary neurosensory disturbances arising from the IAN. The distribution was 11 incidents in the CBCT group and 6 incidents in the PAN imaging group (65). Although, RCTs fulfill the optimal study design for evaluating patient-reported outcomes, they are related to some disadvantages. RCTs are often time-consuming and in addition expensive to conduct, and therefore the number of patients included is often low, resulting in underpowered studies (66).

Epidemiological studies with lower evidence level than RCTs have moreover evaluated the relationship between the use of CBCT for assessment of mandibular third molars and nerve injuries. A register study from Finland (67) concluded that the rapid increase in the availability of CBCT has caused no reduction in the number of permanent IAN injuries related to mandibular third molar removals as reported to the Finnish Patient Insurance Centre. Instead, the number of IAN injuries increased from 1978-1993 to 1997-2007 (67). The interpretation of this result may be that CBCT is of no help to the surgeon, that less experienced surgeons believe they can confidently perform the operation when a CBCT is available, or that more patients nowadays report on nerve injuries. Recently, another epidemiological study of 1627 mandibular third molars reported 16 sensory disturbances to the IAN after full removal of the tooth. Six of these were permanent (0.4%) and ten were temporary (0.6%) (35).

A very recent RCT study also evaluated CBCT versus PAN imaging for other patient-related outcomes than sensory disturbances (68). There were no statistically significant differences between the CBCT and the PAN imaging groups with respect to resources used for surgery (operation time) and post-surgically, nor in resources used for patient complication management, such as post-operative visits at the dental clinic, sickness absence, and use of antibiotics or pain relievers (68). In conclusion, existing studies suggest that CBCT does not change patient outcome compared to PAN imaging, but obviously, more RCTs of removal of third molars in various impaction states and operation complexity are needed.

#### Level 6 - Effect on patient's and societal costs

Evaluation of resource allocation in combination with medical benefits to society is performed in HTA-studies, but only few relate to dentistry (69). One descriptive study estimated costs for a CBCT examination for lower third molars in four countries and concluded that cost evaluation of a dental radiographic method cannot be generalized from one healthcare system to another, but must take into account the specific circumstances. The estimated costs of a CBCT examination varied considerably across the four healthcare systems studied (70).





Only one RCT seems to exist, which has included a calculation of absolute and relative costs prospectively for a CBCT compared with a PAN examination (68). In this RCT it was found that costs for a CBCT examination were 3-4 times the costs for PAN examination when used for treatment planning before mandibular third molar removal. In the study setting, the costs for a CBCT examination varied between approximately € 70 and € 180 (US \$ 95-245), and the costs for a PAN image varied between € 25 and € 50 (US \$ 34-68), depending on variations in capital costs and number of performed examinations yearly. Cost analysis provides an important input for economic evaluations in comparing costs and consequences of diagnostic methods in different healthcare systems, and for planning service delivery in both public and private sectors (70).

Further, when radiographic methods are under evaluation estimates for radiation-derived cancers should be included in assessment of societal costs. One epidemiologic study estimated costs for a CBCT examination if undertaken in all dental clinics in the country before third molar removal (71). Seventeen randomly selected dental clinics in different regions of Den-

mark were visited by two observers, who registered the total number of patients in each clinic and the number of removed lower thirds molars. Approximately 1,400 lower third molars were removed in a sample of 110,000 patients in these general dental practices. Using data from Statistics Denmark gave an estimated number of yearly removed lower third molars of 36,667 at a total cost of about € 6.76 mil (US \$ 9.19 mil). The estimated additional cancer incidence was calculated to 0.46/year, using models reported in the literature (72).

### Conclusions

CBCT is a promising diagnostic method for several tasks in dentistry including assessment of mandibular third molars, but its effectiveness has been sparsely evaluated. Periapical or PAN imaging may be sufficient in most cases before removal of mandibular third molars, but CBCT may be suggested when one or more signs for a close contact between the tooth and the mandibular canal are present in the 2D conventional image - if it is believed that CBCT will change the treatment or the treatment outcome for the patient.

### ABSTRACT (DANSK)

#### **Effekten af at anvende CBCT til at vurdere tredjemolarer i underkæben**

*En røntgenundersøgelse af visdomstanden i underkæben udføres for at hjælpe kirurgen med at lægge en behandlingsplan. Panoramaundersøgelse har været den foretrukne metode til at supplere eller erstatte en periapikal optagelse; men når de konventionelle optagelser viser en overprojektion mellem tredjemolaren og c. mandibulae, og der samtidig er specifikke radiologiske tegn, der indikerer en tæt kontakt mellem n. alv. inf. og tanden, kan der være indikation for at foretage en 3-d-undersøgelse med Cone Beam computer-tomografi (CBCT). Denne oversigtsartikel summerer videnskabelige artikler, der har beskrevet effekten af at anvende CBCT til at vurdere tredje molar i underkæben før fjernelse, og klassificerer disse artikler ved hjælp af en sekstrins hierarkisk model, først publiceret af Fryback og Thornbury (1991).*

*Niveau 1-3 i modellen indeholder studier på lavt evidensniveau, hovedsageligt omfattende tekniske parametre for CBCT-metoden og den diagnostiske rigtighed af billederne. Niveau 4-6 i modellen indeholder studier på højere evidensniveau, idet sådanne studier vurderer røntgenmetodens effekt på behandlingsplanen og på behandlingens resultat, dvs. om patienten har haft gavn af, at denne metode blev anvendt i stedet for en konventionel metode, og niveau 6 ser desuden på effekten for samfundet, herunder de økonomiske omkostninger ved metoden.*

*Der eksisterer ganske få studier, der har undersøgt, om CBCT før fjernelse af en tredje molar i underkæben har nogen effekt for patienten. Foreløbigt må det antages, at CBCT kan anvendes, hvis der er mulighed for, at CBCT-undersøgelsen vil ændre behandlingsplanen for patienten. Der er flere studier i gang med det formål at vurdere, om undersøgelsen er til gavn for patienten.*

Denne artikel er oprindeligt publiceret i: *Dentomaxillofacial Radiology* 2015;44:20140189 (CBCT Special Issue).

## Literature

- Osborn TP, Frederickson G, Small IA et al. A prospective study of complications related to mandibular third molar surgery. *J Oral Maxillofac Surg* 1985;43:767-9.
- Susarla SM, Blaeser BF, Magalnick D. Third molar surgery and associated complications. *Oral Maxillofac Surg Clin North Am* 2003;15:177-86.
- Carmichael FA, McGowan DA. Incidence of nerve damage following third molar removal: a West of Scotland Oral Surgery Research Group study. *Br J Oral Maxillofac Surg* 1992;30:78-82.
- Bataineh AB. Sensory nerve impairment following mandibular third molar surgery. *J Oral Maxillofac Surg* 2001;59:1012-7.
- Gulicher D, Gerlach KL. Sensory impairment of the lingual and inferior alveolar nerves following removal of impacted mandibular third molars. *Int J Oral Maxillofac Surg* 2001;30:306-12.
- Jerjes W, Swinson B, Moles DR et al. Permanent sensory nerve impairment following third molar surgery: a prospective study. *Oral Surg Oral Med Oral Pathol Oral Radiol Endod* 2006;102:e1-7.
- Clark C. A method of ascertaining the relative position of unerupted teeth by means of film radiographs. *Proc Royal Soc Med* 1910;3:87-90.
- Richards AG. A technic for the roentgenographic examination of impacted mandibular third molars. *J Oral Surg (Chic)* 1952;10:138-41.
- Richards AG. Roentgenographic localization of the mandibular canal. *J Oral Surg (Chic)* 1952;10:325-9.
- Sewerin I. Preoperative radiographic examination of the mandibular 3rd molars using 4 projections. 1. Technics. *Tandlægebladet* 1984;88:1-4.
- Sewerin I. Preoperative radiographic study of the lower 3rd molars using 4 projections. 2. 3-dimensional interpretation of films. *Tandlægebladet* 1984;88:50-6.
- Sewerin I. Preoperative radiographic study of the lower 3rd molars using 4 projections. 3. Diagnostic findings. *Tandlægebladet* 1984;88:85-90.
- Schropp L, Stavropoulos A, Gotfredsen E et al. Calibration of radiographs by a reference metal ball affects preoperative selection of implant size. *Clin Oral Investig* 2009;13:375-81.
- Matzen LH, Christensen J, Wenzel A. Patient discomfort and retakes in periapical examination of mandibular third molars using digital receptors and film. *Oral Surg Oral Med Oral Pathol Oral Radiol Endod* 2009;107:566-72.
- Wenzel A, Møystad A. Work flow with digital intraoral radiography: a systematic review. *Acta Odontol Scand* 2010;68:106-14.
- Horner K, Eaton K, eds. Selection criteria for dental radiology. London: Faculty of general dental practice (UK). The Royal College of surgeons of England, 2013.
- SEDENTEXT Project. Radiation protection no 172: cone beam CT for dental and maxillofacial radiology. Luxembourg: European Commission Directorate-General for Energy, 2012.
- Rood JP, Shehab BA. The radiological prediction of inferior alveolar nerve injury during third molar surgery. *Br J Oral Maxillofac Surg* 1990;28:20-5.
- Atieh MA. Diagnostic accuracy of panoramic radiography in determining relationship between inferior alveolar nerve and mandibular third molar. *J Oral Maxillofac Surg* 2010;68:74-82.
- Wenzel A. It is not clear whether commonly used radiographic markers in panoramic images possess predictive ability for determining the relationship between the inferior alveolar nerve and the mandibular third molar. *J Evid Based Dent Pract* 2010;10:232-4.
- Tammisalo E, Hallikainen D, Kanerva H et al. Comprehensive oral X-ray diagnosis: Scanora multimodal radiography. A preliminary description. *Dentomaxillofac Radiol* 1992;21: 9-15.
- Tammisalo T, Happonen RP, Tammisalo EH. Stereographic assessment of mandibular canal in relation to the roots of impacted lower third molar using multiprojection narrow beam radiography. *Int J Oral Maxillofac Surg* 1992;21:85-9.
- Wenzel A, Aagaard E, Sindet-Pedersen S. Evaluation of a new radiographic technique: diagnostic accuracy for mandibular third molars. *Dentomaxillofac Radiol* 1998;27:255-63.
- Flygare L, Öhman A. Preoperative imaging procedures for lower wisdom teeth removal. *Clin Oral Investig* 2008;122:291-302.
- Tetradis S, Kantor M. Extraoral projections and anatomy. In: White S, Pharoah M, eds. *Oral radiology: Principles and interpretation*. St. Louis, Missouri: Mosby Elsevier, 2014;153-65.
- White S, Pharoah M. Other imaging modalities. In: White S, Pharoah M, eds. *Oral radiology: Principles and interpretation*. St. Louis, Missouri: Mosby Elsevier, 2014;229-49.
- Scarfe W, Farman A. Cone-beam computed tomography: Volume acquisition. In: White S, Pharoah M, eds. *Oral radiology: Principles and interpretation*. St. Louis, Missouri: Mosby Elsevier, 2014;185-98.
- Ludlow JB, Davies-Ludlow LE, Brooks SL et al. Dosimetry of 3 CBCT devices for oral and maxillofacial radiology: CB Mercuray, NewTom 3G and i-CAT. *Dentomaxillofac Radiol* 2006;35:219-26.
- Öhman A, Kull L, Andersson J et al. Radiation doses in examination of lower third molars with computed tomography and conventional radiography. *Dentomaxillofac Radiol* 2008;37:445-52.
- Ludlow JB, Davies-Ludlow LE, Brooks SL. Dosimetry of two extraoral direct digital imaging devices: NewTom cone beam CT and Orthophos Plus DS panoramic unit. *Dentomaxillofac Radiol* 2003;32:229-34.
- Ludlow JB, Ivanovic M. Comparative dosimetry of dental CBCT devices and 64-slice CT for oral and maxillofacial radiology. *Oral Surg Oral Med Oral Pathol Oral Radiol Endod* 2008;106:106-14.
- Maret D, Telmon N, Peters OA et al. Effect of voxel size on the accuracy of 3D reconstructions with cone beam CT. *Dentomaxillofac Radiol* 2012;41:649-55.
- Spin-Neto R, Gotfredsen E, Wenzel A. Impact of voxel size variation on CBCT-based diagnostic outcome in dentistry: a systematic review. *J Digit Imaging* 2013;26:813-20.
- Scarfe W, Farman A. Cone-beam computed tomography: Volume preparation. In: White S, Pharoah M, eds. *Oral Radiology: Principles and interpretation*. St. Louis, Missouri: Mosby Elsevier, 2014;199-213.
- Matzen LH, Schou S, Christensen J et al. Audit of a 5-year protocol for assessment of mandibular third molars before surgical intervention. *Dentomaxillofac Radiol* 2014;43:20140172.
- Fryback DG, Thornbury JR. The efficacy of diagnostic imaging. *Med Decis Making* 1991;11:88-94.
- White S, Pharoah M. Safety and protection. In: White S, Pharoah M, eds. *Oral Radiology: Principles and interpretation*. St. Louis, Missouri: Mosby Elsevier, 2014;29-40.
- Azaz B, Shteyer A, Piamanta M. Radiographic and clinical manifestations of the impacted mandibular third molar. *Int J Oral Surg* 1976;5:153-160.
- Benediktsdottir IS, Wenzel A. Accuracy of digital panoramic images displayed on monitor, glossy paper, and film for assessment of mandibular third molars. *Oral Surg Oral Med Oral Pathol Oral Radiol Endod* 2004;98:217-22.
- Suomalainen A, Venta I, Mattila M et al. Reliability of CBCT and other radiographic methods in preoperative evaluation of lower third molars. *Oral Surg Oral Med Oral Pathol Oral Radiol Endod* 2010;109:276-84.
- Matzen LH, Christensen J, Hintze H et al. Diagnostic accuracy of panoramic radiography, stereoscanography and cone beam CT for assessment of mandibular third molars before surgery. *Acta Odontol Scand* 2013;71:1391-8.
- Tantanapornkul W, Okouchi K, Fujiwara Y et al. A comparative study of cone-beam computed tomography and conventional panoramic radiography in assessing the topographic relationship between the mandibular canal and impacted third molars. *Oral Surg Oral Med Oral Pathol Oral Radiol Endod* 2007;103:253-9.
- Ghaemina H, Meijer GJ, Soehardi A et al. Position of the impacted third molar in relation to the mandibular canal. Diagnostic accuracy of cone beam computed tomography compared with panoramic radiography. *Int J Oral Maxillofac Surg* 2009;38:964-71.
- Guerrero ME, Shahbazian M, Elsiensia Bekering G et al. The diagnostic efficacy of cone beam CT for impacted teeth and associated features: a systematic review. *J Oral Rehabil* 2011;38:208-16.
- Nakagawa Y, Ishii H, Nomura Y et al. Third molar position: reliability of panoramic radiography. *J Oral Maxillofac Surg* 2007;65:1303-8.
- Tantanapornkul W, Okouchi K, Bhakdinaronk A et al. Correlation of darkening of impacted mandibular third molar root on digital panoramic images with cone beam computed tomography findings. *Dentomaxillofac Radiol* 2009;38:11-6.
- Kositbowornchai S, Densiri-aksorn W, Piumthanoj P. Ability of two radiographic methods to identify the closeness between the mandibular third molar root and the inferior alveolar canal: a pilot study. *Dentomaxillofac Radiol* 2010;39:79-84.
- Dalili Z, Mahjoub P, Sigaroudi AK. Comparison between cone beam computed tomography and panoramic radiography in the assessment of the relationship between the mandibular canal and impacted class C mandibular third molars. *Dent Res J (Isfahan)* 2011;8:203-10.
- Jung YH, Nah KS, Cho BH. Correlation of panoramic radiographs and cone beam computed tomography in the assessment of a superimposed relationship between the mandibular canal and impacted third molars. *Imaging Sci Dent* 2012;42:121-7.
- Neves FS, Souza TC, Almeida SM et al. Correlation of panoramic radiography and cone beam CT findings in the assessment of the relationship between impacted mandibular third molars and the mandibular canal. *Dentomaxillofac Radiol* 2012;41:553-7.
- Harada N, Vasudeva S, Joshi R et al. Correlation between panoramic radiographic signs and high-risk anatomical factors for impacted mandibular third molars. *Oral Surg* 2013;6:129-36.
- Shahidi S, Zamiri B, Bronoosh P. Comparison of panoramic radiography with cone beam CT in predicting the relationship of the mandibular third molar roots to the alveolar canal. *Imaging Sci Dent*

2013;43:105-9.

53. Sekerci A, Sisman Y. Comparison between panoramic radiography and cone-beam computed tomography findings for assessment of the relationship between impacted mandibular third molars and the mandibular canal. *Oral Radiol* 2014;30:170-8.

54. Matzen LH, Hintze H, Spin-Neto R et al. Reproducibility of mandibular third molar assessment comparing two cone beam CT units in a matched pairs design. *Dentomaxillofac Radiol* 2013;42:20130228.

55. Ghaemina H, Meijer GJ, Soehardi A et al. The use of cone beam CT for the removal of wisdom teeth changes the surgical approach compared with panoramic radiography: a pilot study. *Int J Oral Maxillofac Surg* 2011;40:834-9.

56. Dolanmaz D, Yildirim G, Isik K et al. A preferable technique for protecting the inferior alveolar nerve: coronectomy. *J Oral Maxillofac Surg* 2009;67:1234-8.

57. Renton T, Hankins M, Sproate C et al. A randomised controlled clinical trial to compare the incidence of injury to the inferior alveolar nerve as a result of coronectomy and removal of mandibular third molars. *Br J Oral Maxillofac Surg* 2005;43:7-12.

58. Pogrel MA. Partial odontectomy. *Oral Maxillofac Surg Clin North Am* 2007;19:85-91.

59. Leung YY, Cheung LK. Safety of coronectomy versus excision of wisdom teeth: a randomized controlled trial. *Oral Surg Oral Med Oral Pathol Oral Radiol Endod* 2009;108:821-7.

60. Leung YY, Cheung LK. Can coronectomy of wisdom teeth reduce the incidence of inferior dental nerve injury? *Ann R Australas Coll Dent Surg* 2008;19:50-1.

61. Cilasun U, Yildirim T, Guzeldemir E, Pektas ZO. Coronectomy in patients with high risk of inferior alveolar nerve injury diagnosed by computed tomography. *J Oral Maxillofac Surg* 2011;69:1557-61.

62. Knutsson K, Lysell L, Rohlin M. Postoperative status after partial removal of the mandibular third molar. *Swed Dent J* 1989;13:15-22.

63. Matzen LH, Christensen J, Hintze H et al. Influence of cone beam CT on treatment plan before surgical intervention of mandibular third molars and impact of radiographic factors on deciding on coronectomy vs surgical removal. *Dentomaxillofac Radiol* 2013;42:98870341.

64. Guerrero ME, Botetano R, Beltran J et al. Can preoperative imaging help to predict postoperative outcome after wisdom tooth removal? A randomized controlled trial using panoramic radiography versus cone-beam CT. *Clin Oral Investig* 2014;18:335-42.

65. Petersen LB, Christensen J, Olsen K et al. Postoperative complications after mandibular third molar removal based on panoramic radiography or cone beam CT-scanning: a randomized controlled clinical study. *EADMF 2012 (Abstr OP 113)*.

66. Roeder F, Wachtlin D, Schultze R. Necessity of 3D visualization for the removal of lower wisdom teeth: required sample size to prove non-inferiority of panoramic radiography compared to CBCT. *Clin Oral Investig* 2012;16:699-706.

67. Suomalainen A, Apajalahti S, Vehmas T et al. Availability of CBCT and iatrogenic alveolar nerve injuries. *Acta Odontol Scand* 2013;71:151-6.

68. Petersen LB, Christensen J, Olsen K et al. Image and surgery-related costs comparing cone beam CT and panoramic imaging before removal of impacted mandibular third molars. *Dentomaxillofac Radiol* 2014;20140001.

69. Petersen LB, Christensen J, Olsen K et al. Medicinsk teknologivurdering inden for odontologi. *Tandlægebladet* 2012;116:726-34.

70. Christell H, Birch S, Hedesiu M, et al. Variation in costs of cone beam CT examinations among health-care systems. *Dentomaxillofac Radiol* 2012;41:571-7.

71. Petersen LB, Matzen LH, Olsen K et al. Economic implications of routine CBCT examination before surgical intervention of the lower third molar in the Danish population. *EADMF 2014 (Abstr OP 7B 2)*.

72. Hall EJ, Brenner DJ. Cancer risks from diagnostic radiology. *Br J Radiol* 2008;81:362-78.

Denne artikel er oprindeligt publiceret i: *Dentomaxillofacial Radiology* 2015;44:20140189 (CBCT Special Issue).

## Appendix

Parts of this review are based on a phd thesis: Matzen LH. Radiographic methods for the assessment of impacted mandibular third molars. PhD thesis, Aarhus University Press, 2013.

The search criteria for the studies extracted for the present review with regard to evidence on the use of CBCT for radiographic examination of mandibular third molars is seen in Table

A1 and A2. The search was made for the following topic: Third molar, CBCT, alveolar inferior nerve/mandibular nerve. The searches were conducted 13-20 May 2014. From the search in the PubMed database 184 titles from one search and 312 titles from another search have been read and 346 from search in the Embase database, moreover a hand search has been made.

### Search in PubMed database

A	B	C	D
Free text search			Free text search
1: CBCT "third molar" mandibular 38	1: "molar third" Mesh 4593	1: "molar third" Mesh 4593	1: Mandibular Nerve OR "third Molar" OR "Third molars" AND Cone-Beam Computed Tomography OR cbct OR "cone-beam CT" <b>184</b>
2: "mandibular canal" 642	2: "Mandibular nerve" Mesh 3163	2: "Mandibular nerve" Mesh 3163	2: Mandibular Canal OR "third Molar" OR "Third molars" AND Cone-Beam Computed Tomography OR cbct OR "cone-beam CT" <b>312</b>
		3: Cone-beam computed tomography OR cone-beam CT Mesh 4885	
3: "mandibular canal" CBCT "molar third" 12	1 OR 2 7473	1 OR 2 and 3 118	

**Table A1.** Search in PubMed database to achieve publications examined for the review. Title numbers in bold have been assessed.

**Tabel A1.** Søgning for at finde studier egnet til dette review i PubMed databasen. Antallet markeret med fed er blevet vurderet.

## Search in Embase database

A	B	C
"molar tooth" 24,587	mandibular AND "nerve" OR nerve OR "third molar" OR "third molars" 31,833	Free text "inferior alveolar nerve" OR "mandibular nerve" OR "molar tooth" AND "cone beam computed tomography" <b>346</b>
"third molar" OR "third molar" OR "third molars" OR "wisdom tooth" OR "wisdom tooth" OR "wisdom teeth" 27,024 "cone beam" AND computed AND "tomography" OR tomography OR cbct OR "cone-beam ct" OR "cone-beam ct" 6,893 "inferior alveolar nerve" 875 "mandibular nerve" 3,072		

**Table A2.** Search in Embase database to achieve publications examined for the review. Title numbers in bold have been assessed.

**Tabel A2.** Søgning for at finde studier egnet til dette review i Embase databasen. Antallet markeret med fed er blevet vurderet.



SACD – en av Sveriges ledande utbildningsorganisationer inom estetisk tandvård – i samarbete med Praktikertjänst, välkomnar alla tandläkare och team till SACD's årsmöteskurs

## Lär dig mer om två trender i tiden

Torsdag 26 – lördag 28 november, Grand Hôtel, Stockholm

9 900 SEK + moms för tandläkare och tandtekniker, 4 900 SEK + moms för teammedlemmar. Bra avtalspriser för hotellvistelse.

Två föreläsare i världsklass – **Dr Christian Coachman**, examinerad i Dental Technology och i Dentistry vid University of São Paulo-USP/Brazil och medlem i AAED, och **Kristin Heinonen**, digital strateg och expert på trender på internet och sociala medier. OBS! Föreläsningarna sker på engelska respektive svenska.

### The Virtual Lab. The Future Now!

The Dental Laboratory of the future will become the starting point of any interdisciplinary treatment plan, the key partner for increasing case acceptance, will utilise softwares to transform our restorative experience into something much more efficient, predictable and beautiful. Some of the realistic processes and new technology will be shared on this lecture. The future is now!



Christian Coachman



Kristin Heinonen

### Sociala medier och digital marknadsföring

En heldagsutbildning för dig som vill utveckla marknadsföring och kommunikation med hjälp av smarta digitala lösningar. Konkreta fall blandas med handfasta tips och fakta och den senaste digitala utvecklingen.



Swedish Academy of  
Cosmetic Dentistry

För information och anmälan se [www.sacd.se](http://www.sacd.se) och [www.praktikertjanst.se](http://www.praktikertjanst.se) eller kontakta [helene@hfconsulting.se](mailto:helene@hfconsulting.se)

 Praktikertjänst