

ABSTRACT

Improving communications with the dental technician

The purpose of this first case report was to evaluate video material as a communication tool with the dental technician. A lightweight loupe mounted HD-video camera was used to capture the viewpoint of the dentist and the dental technician during the daily work. The verbal instruction was recorded as well. In three representative cases the video material with the verbal instructions and photographs formed an essential part of the communication to enhance the cooperation of the dental technician and the dentist.

Using video material for communication with the dental technician

Peter Rusanen, dentist, M.Sc. dental prosthetics and oral rehabilitation, University of Helsinki, Helsinki, Finland

Mikko Kääriäinen, dental technician, Ceramikko Ltd, Helsinki, Finland

Kirsi Sipilä, professor, Institute of Dentistry, University of Eastern Finland, Finland, and Oral and Maxillofacial Department, Kuopio University Hospital, Finland

In order to obtain the best possible results in prosthodontics, it is essential that the dentist and dental technician work together effectively as a team. Each should have a sound understanding of the role of the other so that they can cooperate fully(1). Dental technicians are at a great disadvantage since they are usually not able to actually see the patient. Therefore, a digital photo can fill that important missing link (2). In cases where the dental technician does not meet the patient in person, the teamwork can only be as good as the level of information the technician receives. The technician's input in the teamwork starts with the translation of two-dimensional design diagrams, photographs and written instructions into the three-dimensional reality. Nevertheless, accurate instructions to the dental lab technician play an essential role to achieve the required outcome (1).

Traditionally dentists communicate with their technicians (and vice versa) in a variety of ways, for example written instructions, drawings and phone calls. In addition to an impression, static analysis (e.g.a photograph) is used to enhance the communication. From photography, the colour of teeth, smile line and prevailing situation of the patient can easily be seen. Dental photography can significantly enhance the level of treatment provided (3). However, a static picture does not have the information about the movements of different oral parts which can be crucial for the dental technician. The selection of the way to communicate is dictated by the treatment. For the evaluation

of the aesthetics of the smile authors Sousa and Tsingene propose a new Smiles Aesthetic Evaluation Form (SAEF). It uses both static (photographs) and dynamic (videos) analysis, followed by several objective and subjective items,

EMNEORD

Video; digital; communication; photography; dental technician

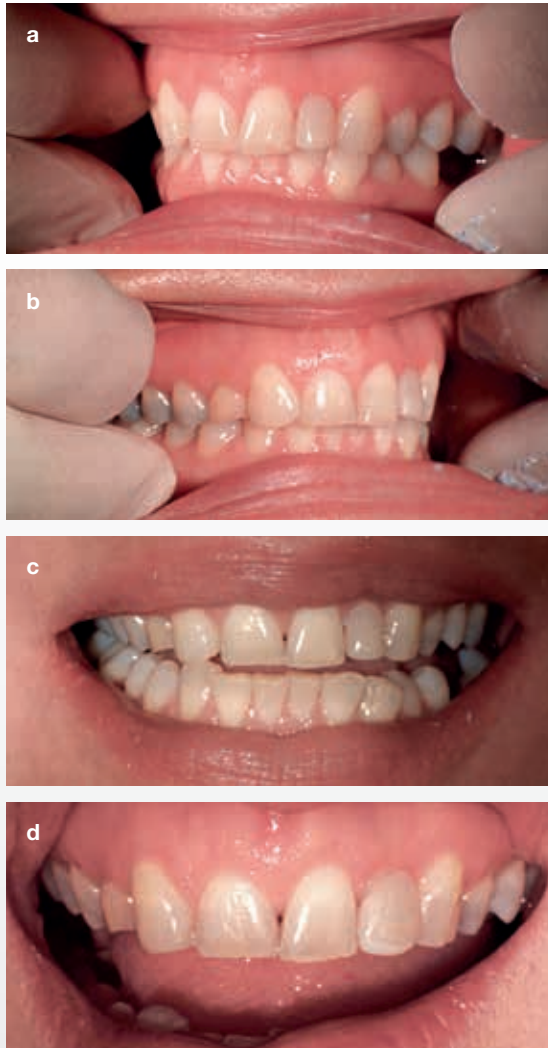


Fig. 1a,b,c,d. Photographs taken with loupe mounted HD-camera of the initial condition sent to the dental technician. Patient was dissatisfied on the asymmetric appearance in the front area as well as on the suboptimal inclination and on the dark color of the second left incisor.

thus improving the communication between the different dental specialists and laboratory technicians (4). However, in general video material is rarely used as a daily communication tool because it traditionally requires much time and effort to process in order to share effectively with the dental technician. To send video material and photographs by email is problematic not only because of the large file size but also because of the lack of security. Nevertheless, in order to minimize the potential for remakes and miscommunication there is a need for a more efficient way to communicate. High-level cooperation across distances requires

modern technology to communicate expectations and potential outcomes (5). In order to enhance the communication between dentist and dental technician it is essential that production of high quality images and videos and sharing these suits daily workflow and does not require additional effort.

Material and methods

The video camera system used in three representative cases has been developed in the central hospital of Helsinki University, among dentists in specialist training. It has mainly been used for education, consultation and for the communication with the dental technician. The camera system is based on three essential parts; a loupe-attached lightweight HD-video camera, the recording software and a secure website. This enables capture of whatever the dentist sees through the loupes, and without editing, securely shares videos over the Internet. Similarly, the dental technician can attach the camera to the microscope. The video camera can also be used as a digital camera and records audio if required. The software allows edit-free use of videos: during a recording, the user can, by pressing a pedal, highlight, (bookmark), points in the video that are important and during playback the viewer can easily jump between highlights. The software is unique in the way it handles video files. The benefit is that nothing is cut out, and depending on the circumstances, the videos can be scrolled through quickly, or presented very flexibly, showing each part for as long as desired, and going back to any point in the video. After recording, the video and photographs were anonymised and uploaded to the secure website, using SSL. From the personal account in the website the videos and images were shared to the recipient.

Thus this system shared information in form of still images, video material and also verbal explanation. The verbal instructions were simultaneously recorded by the video camera during recording both the dentist's view and through the microscope. The computer used in these cases was Lenovo Think Pad with Intel Centrino, Windows Vista. All patients gave oral consent for the use of these videos and photographs for this research. The consent was filed to the patient information system.

Results

Three representative cases, where photographs and video material formed an essential part of communication between the dentist and dental technician, are described below. All videos and photographs were recorded with the video camera system.

1. Video used to receive feedback from the dental technician

The patient was dissatisfied with aesthetics of the front area. The right second incisor was missing congenitally and the left second incisor was filled with composite. The gap on the right side had been eliminated by an orthodontic treatment in childhood. The patient was dissatisfied with the suboptimal inclination and the dark colour of the second left incisor, and in addition patient with the asymmetric appearance in the front area, (Fig.1a,b,c), but did not want extensive treatment.



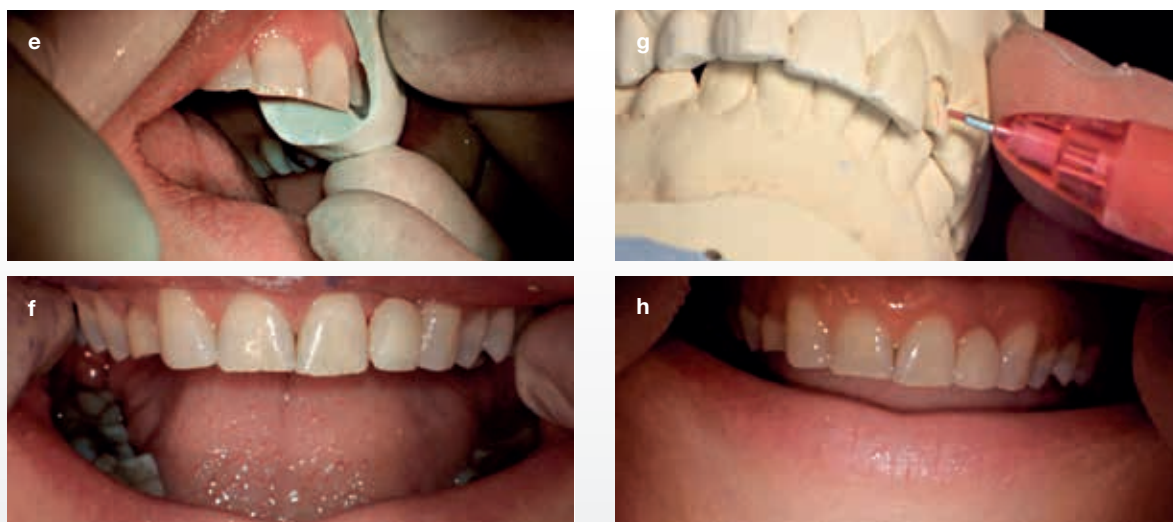


Fig. 1e,f,g,h. Photographs (e,h) and still images of video (f,g) taken with loupe mounted HD-camera sent to the dental technician. The mock up was made on the second left lateral according to the wax up (e). After the confirmation of the patient the right canine was restored with composite and the second left lateral was prepared and the impression was taken (f,g). After the impression the temporary crown was made according to the wax up (h).

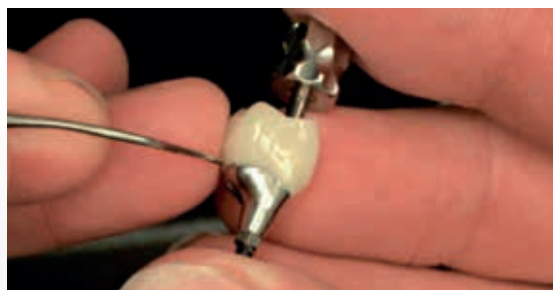


Fig. 2. Still image of a video combined with a verbal explanation taken with loupe mounted HD-camera. The implant-retained crown did not fulfil the expectations of the dentist and the feedback was given to the dental technician with a video combined with a verbal explanation.

The treatment plan was based on the wax up and the dentist and the patient decided to restore the second left incisor with a porcelain crown, and to achieve a more symmetrical appearance in the front area by filling the mesial corner of the right canine with composite (Fig.1d,e,f).

From the first impression it appeared that the gingival margin was left too coronally to achieve more symmetry. In addition the tooth was not adequately prepared on the buccal side (Fig.1g).

All the steps were recorded and videos and photographs were shared between the dentist and dental technician. The dental technician sent a video with a verbal explanation about preparation of the areas around the tooth in order to achieve a better aesthetic result. Followed receipt of these instructions, treatment continued as planned, and the patient was satisfied with the end result (Fig.1h).

2. Video used to give feedback to the dental technician

A dentist started to work with a new dental technician and the first implant-retained crown did not meet the expectations of the dentist. Feedback was given by video combined with a verbal explanation (Fig.2). The dental technician accordingly re-made the implant-retained crown and the teamwork between the dentist and dental technician reached a higher level.

3. Video used to receive crucial information from the dental technician

In a prosthetic treatment in the front area the dentist noticed a defect in the impression on the palatal side of the second left lateral incisor. Unfortunately there was no time to remake the impression and the treatment continued as planned (Fig. 3a,b,c).

After creating a model of a patient's mouth by pouring plaster into the impression, the technician examined the model. The dental technician shared a video in which he prepared the defect on the plaster cast and managed to find the preparation line reliably (Fig. 3d,e,f). The crown was made



CLINICAL RELEVANCE

It is essential that the dentist and dental technician work together effectively as a team. A video allows the dental technician receives significantly extra information about patient's intraoral condition: movements of lower jaw, resilience of the oral mucosa, smile line and colour

of teeth can easily be seen. In addition the dentist can receive essential information from the dental technician. Video material enhances the communication with the dental technician and a higher level of co-operation is reached.

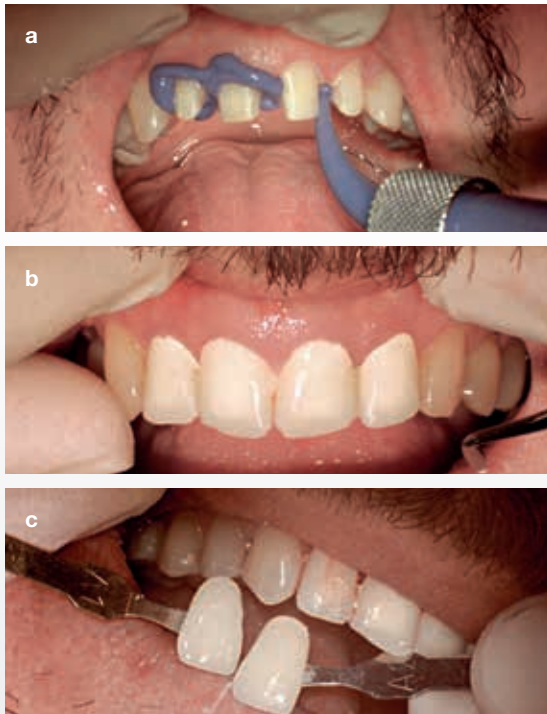


Fig. 3a,b,c. Photographs taken during the operation sent to the dental technician. After the preparation in the frontal area the impression was taken and the temporary crowns was made (a,b). Photographs used to define the colour and translucency in the frontal area (c).

as planned and the dentist was confident with the fit on the patients tooth (Fig. 3g).

Advantages

High quality video material is a superior way to communicate:

1. The dental technician can see the whole operation. This enables the technician to understand more about the intraoral situation and the prepared teeth.
2. Still images and videos, with verbal instruction, shared over the Internet reaches both parties at the same time and doesn't require the dentist and the dental technician to meet together. Comments, questions and additional information can easily be added at any time.
3. To give or receive video feedback, with verbal instructions, over the Internet is effective and enables better teamwork.
4. From a video the resilience of oral mucosa can easily be seen. The dental technician can see the movements of lower jaw, lips, smile line, tongue, frenulae, floor of the mouth and soft palate for example.

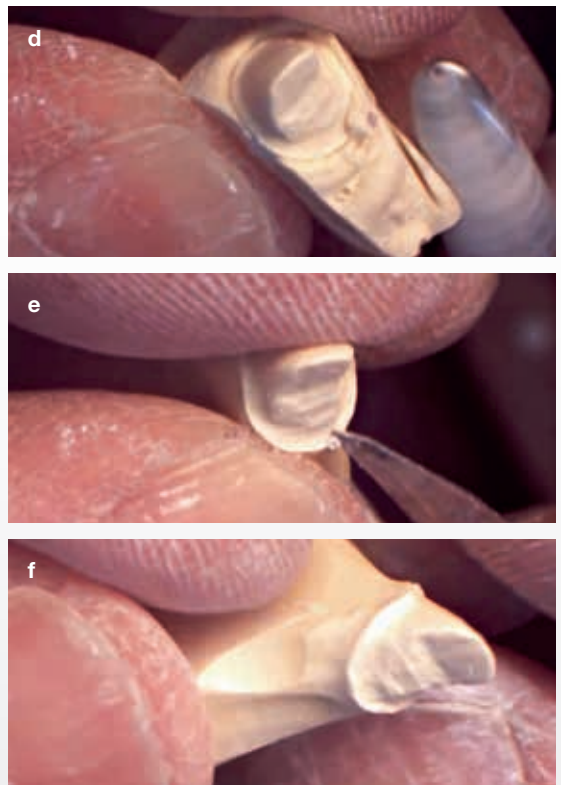


Fig. 3d,e,f. Still images of the video the dental technician sent to the dentist taken with loupe mounted HD-camera. The dentist noticed a defect in the impression but there was no time to remake the impression. The dental technician shared the video where he prepared the defect on the plaster cast and managed to find the preparation line reliably (d,e,f).

Discussion

Shooting a high quality photography or video material within the oral cavity is challenging for several reasons. It traditionally requires an additional person to hold the video camera, unless the camera is attached to a lever arm or to the lamp. This leads to video or photographs which are not shot from the same angle as the operator's view, inevitably leading to shadows and barriers in front of the video camera, especially in operations made in the back of the mouth. In addition the video requires editing, which is time consuming, and it requires knowledge of the editing programs. Until now, it was not possible to attach the video camera on loupes to capture video and take photographs without interruption from the operators view.

Even if the patient is unrecognizable in the video or in photographs and the recorded material is treated anonymously, the legislation covering use of this material differs between Nordic countries. Commonly the consent for the use of the recorded material is requested from the patient. For a secure handling or sharing videos or photographs over the Internet, it is essential to use SSL encryption.

According to our preliminary results, video material combined with photographs enabled better teamwork. Giving the instructions using simultaneous dynamic images (video) and verbal instructions in addition to static images (photographs), the dental technician receives significantly more information compared to the traditional way. Furthermore, the technician can show to the dentist the specific and essential details of the case.

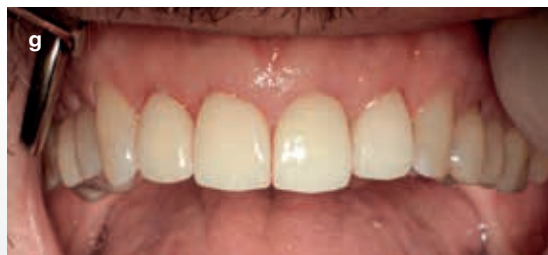

Fig. 3g. Photograph from the end result sent to the dental technician as a feedback of excellent work.

Despite the fact that the sample size is quite limited, the results are promising and further studies are suggested. Forthcoming technologies used in the video camera system allow dentist-technician team to reach to a significantly higher level of cooperation. In the future, video material will play a significantly more important part in communication in a treatment team.

Acknowledgements

The concept of the Futudent HD camera system is based on Peter Rusanen's idea to enhance the communication in the dentistry and is a founder of this early state start up company. MDT Mikko Kääriäinen and Prof Kirsi Sipilä don't have any conflict of interests.

Litteratur

1. Davenport JC, Basker RM, Heath JR et al. Communication between the dentist and the dental technician. *Br Dent J* 2000;189:471-4.
2. Griffin JD Jr. Excellence in photography: heightening dentist-ceramist communication. *Dent Today* 2009;28:124-7.
3. McLaren EA, Schoenbaum T. Digital photography enhances diagnostics, communication, and documentation. *Compend Contin Educ Dent* 2011;32:36-8.
4. Sousa Dias N, Tsingene F. SAEF - Smile's Aesthetic Evaluation form: a useful tool to improve communications between clinicians and patients during multidisciplinary treatment. *Eur J Esthet Dent* 2011;6:160-76.
5. Schoenbaum TR, Chang YY. Dentist-technician collaboration in the digital age: enhancing outcomes through photography, teamwork, and technology. *J Calif Dent Assoc* 2011;39:559-67.

Det Sundhedsvidenskabelige Fakultet

Final announcement



KASUISTIK-SYMPOSIUM PÅ TANDLÆGESKOLEN fredag og lørdag den 24. og 25. januar 2014

Program

Dag	Emner	Foredragsholdere
Fredag *	Åbning	v/ konst. institutleder Anne Marie Lyng Pedersen
8.00- ca.12.00	Pædagogik, Ortodonti, Cariologi, Endodonti, Oral medicin	Eva Lauridsen, Lars Bjørndal, Vibeke Qvist, Liselotte Sonnesen, Jette Daugaard, Jesper Reibel
<i>Frokost</i>		
ca.12.40- 15.30	Parodontologi, Kosmetisk tand- behandling, Endodonti, Future perspectives in 3D imaging	Anne Havemose, Ulla Pallesen, Lars Bjørndal Michael Bornstein
Lørdag		
8.00 ca.12.00	Cariesforebyggelse på ny, Oral Rehabilitering og Dental Materialer	Svante Twetman, Ulla Pallesen, Klaus Gotfredsen, Esben Boeskov Øzhayat, Lars Poulsen, Sharifah Abdullah Jakob Lempert, Lone Forsberg, Betty Holm, Ana Benetti.
<i>Frokost</i>		
ca.12.40- 15.00	Kæbeledsdiagnostik og røntgen, Oral Kirurgi	Merete Bakke Malene Hallund, Lars Pallesen, Thorkild Knudsen.

* Parallel program for klinikassistenter om fredagen

Detaljerede program og tilmelding se:

www.odontefteruddannelse.ku.dk/evoi/

Venlig hilsen

konst. Institutleder Anne Marie Lyng Pedersen

Goldsponsorer

PLANMECA
PLANMECA
PLANMECA



Colgate®

YOUR PARTNER IN ORAL HEALTH

