

ABSTRACT

OBJECTIVE - To evaluate the three-dimensional effects of orthodontic treatment on the airway in children using cone beam computed tomography (CBCT).

METHOD - A review of the literature was performed using several databases (PubMed, Scopus, Embase, Web of Science). The electronic search was followed up with manual searches of reference lists to identify any further studies for inclusion.

RESULTS - Eighteen studies were identified which utilized CBCT to assess orthodontic treatment effects on the upper airway in children in three dimensions (eight functional appliance (FA); five rapid maxillary expansion (RME); three class III correctors; two extraction vs non-extraction).

CONCLUSION - RME is not associated with a significant change in upper airway volume and airway constriction whereas FAs are associated with significant positive changes. There is limited evidence that using FA in children with obstructive sleep apnoea and mandibular retrognathia may eliminate symptoms and prevent the disease continuing into adulthood. Treatment of maxillary retrognathia using reverse pull headgear may be associated with positive changes in the upper airway. Orthodontic extractions are not associated with negative effects on the upper airway in children.

EMNEORD Orthodontics | airway | cone beam computed tomography | rapid maxillary expansion | functional appliance



Korrespondanceansvarlig førsteforfatter:

YOUSEF ABDALLA

dr.yousef.abdalla@gmail.com

Effects of orthodontics on the upper-airway in children

YOUSEF ABDALLA, ph.d.-student, BDS, DClintDent, Section of Orthodontics, Department of Odontology, Faculty of Health and Medical Sciences, University of Copenhagen

LISELOTTE SONNESEN, professor mso and director of postgraduate program in orthodontics and the dental sleep clinic, dr.odont. ph.d., Section of Orthodontics, Department of Odontology, Faculty of Health and Medical Sciences, University of Copenhagen

► Accepteret til publikation den 2. juli 2020

Tandlægebladet 2020;124:xxx-xxx

BOTH MANDIBULAR RETROGNATHIA AND A NARROW MAXILLA are risk factors for reduced upper airway volume in children (1). Rapid maxillary expansion (RME) exerts a transverse force across the maxilla and is commonly used in orthodontics to correct arch width discrepancies, whilst also having a skeletal effect of increasing maxillary width (2). Likewise, functional appliances (FA) are orthodontic appliances used to correct mandibular retrognathia by holding the mandible in a protrusive position for an extended time period (3). Although the treatment objectives differ, mandibular advancement devices (MAD) share the same mechanical and design principals as FA. MAD have been shown to increase upper airway patency (4) and are used in the treatment of adults with obstructive sleep apnoea (OSA) who cannot tolerate continuous positive airway pressure therapy (CPAP) (5).

There are clearly potential associations between skeletal changes elicited with orthodontic appliances and upper airway dimensions. Historically, these associations have been difficult to assess due to the use of 2-dimensional imaging in orthodontics. As the upper airway is a complex three-dimensional structure (6), 2-dimensional imaging provides a limited means of assessment.

Traditional 3-dimensional imaging methods, such as magnetic resonance imaging (MRI) and medical computed tomography (CT) are seldom used in orthodontics. This is mainly due to limitations of cost and, in the case of CT, a high radiation dose (7). Cone beam computed tomography (CBCT) is a relatively new 3-dimensional imaging technique. It can differentiate between the airway and soft tissues with high resolution. CBCT offers distinct advantages over MRI and CT, such as a lower radiation dose, lower cost, easier access and shorter acquisition

Literature Search

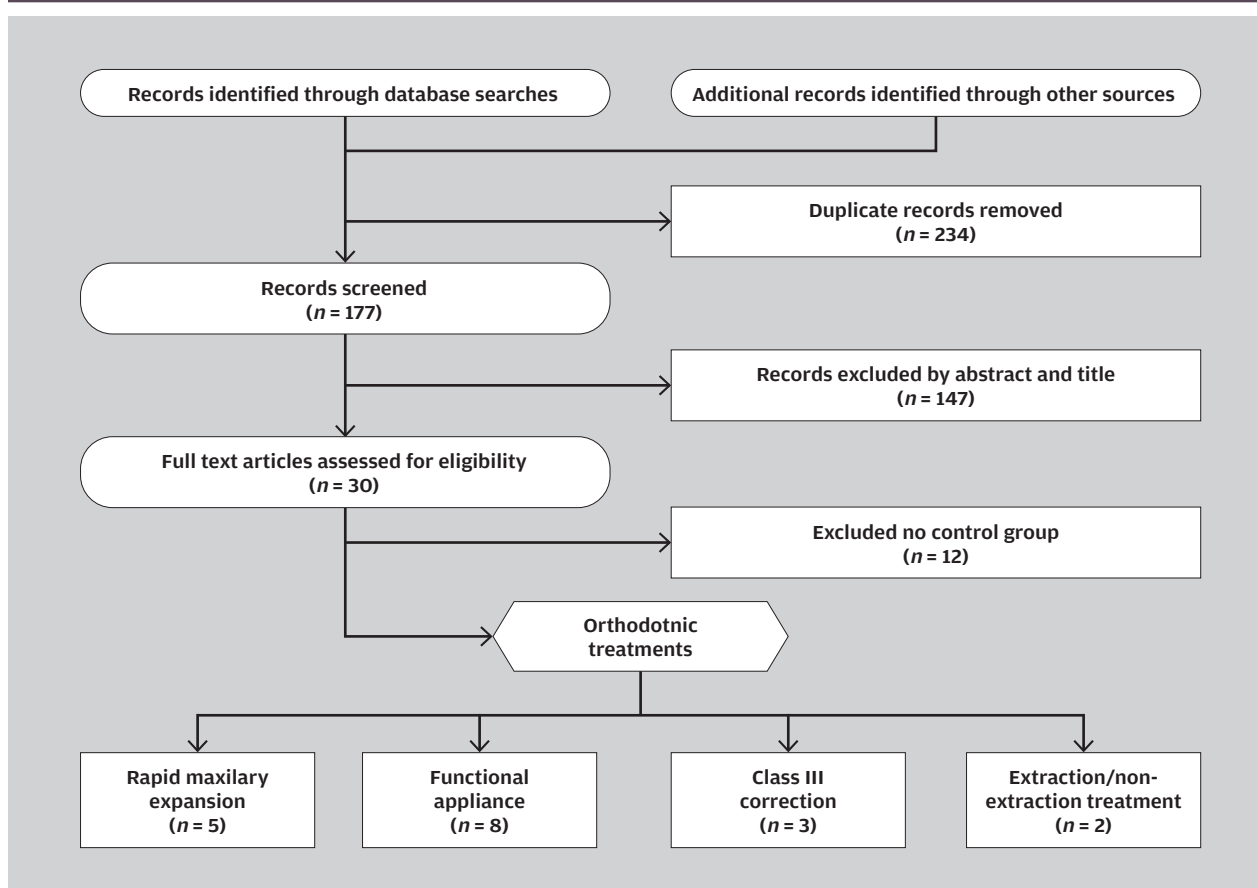


Fig. 1. Results of the literature search using the following search term: (((orthodont*) AND airway) AND (cone beam computed tomography OR cone beam CT OR cone-beam CT OR CBCT OR 3D volumetric computed tomography OR volume computed tomography OR 3D OR 3-D OR three dimensions OR three-dimensional OR three-dimension) AND (child* OR adolescent)).

Fig. 1. Resultaterne fra litteratursøgningen ved brug af følgende termer: (((orthodont*) OG airway) OG (cone beam computed tomography ELLER cone beam CT ELLER cone-beam CT ELLER CBCT ELLER 3D volumetric computed tomography ELLER volume computed tomography ELLER 3D OR 3-D ELLER three dimensions ELLER three-dimensional ELLER three-dimension) OG (child* ELLER adolescent)).

time (8). The aim of the present paper was to review the literature to determine the 3-dimensional effects orthodontic treatment has on the upper airway in children, using CBCT imaging.

MATERIAL AND METHOD

A search of four databases was carried out (Pubmed, Embase, Scopus and Web of Science) with the following inclusion criteria:

- Participants:** Children or adolescents (< 18 years age)
- Intervention:** Orthodontic treatment with any orthodontic appliance
- Comparison:** Non-treatment or alternative treatment control group.
- Outcome:** Effects on airway volume and/or airway constriction assessed with CBCT

Reference lists of included studies were manually searched to identify further studies for inclusion. Once duplicates were

removed, this resulted in 177 studies. Following review of abstracts and the full texts, there were 18 identified studies: 5 RME; 8 FA; 3 class III correction; and 2 extraction/non extraction studies (Fig. 1). Search limits were set to studies in English only.

RESULTS

Most of the research into the effects of orthodontic appliances on the airway have been limited in the past due to the technological limitations of cephalometric imaging, meaning that only the anterior-posterior airway dimensions could be measured. Consequently, analysis of the medio-lateral airway dimension was not possible (Fig. 2) (9). A small number of studies have used CBCT to further increase understanding of how mandibular advancement and maxillary expansion affect the airway in children (10,11). ▶

Upper airway imaging

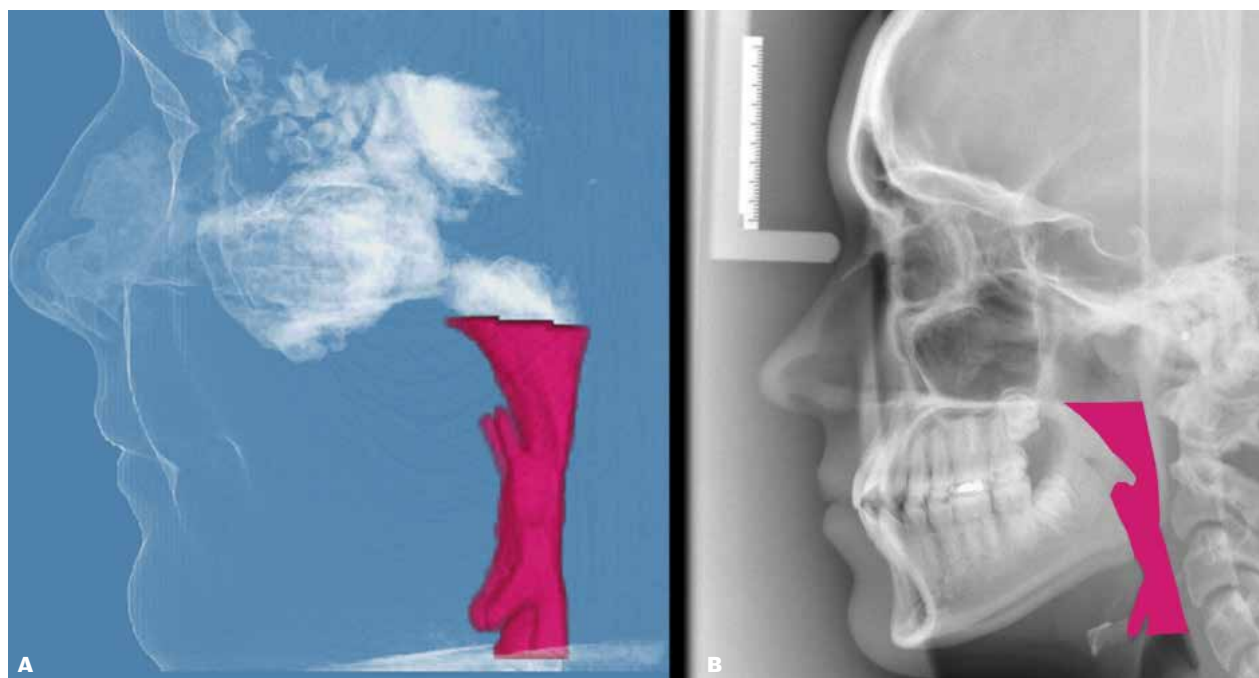


Fig. 2. Illustration of (A) three-dimensional measurement of upper airway using CBCT and (B) traditional cephalometric radiographs.
Fig. 2. Illustration af (A) tre-dimensionel måling af øvre luftvej på CBCT og (B) traditionel lateral profil røntgenbillede.

Functional Appliances

Mandibular retrognathia is one of the most prevalent skeletal anomalies affecting Caucasian populations (12) and the use of FA are a common form of orthodontic correction (13). Regardless of design, FA work by posturing the mandible forwards for an extended time and, if used in growing patients, are thought to influence mandibular growth.

The mechanism by which this is achieved remains controversial (14). Some studies show changes being primarily dento-alveolar whereas others show changes being more skeletal (15). A significant limitation in most studies is that changes achieved with FA are not assessed relative to stable structures in the facial skeleton. Using implants, Björk (16) has shown that cephalometric reference points used to measure skeletal changes are themselves moving over time. Consequently, they are not a stable reference from which to measure changes. This may be a reason why there is such disagreement in the literature regarding the skeletal effects of these appliances (17).

Airway volume

Of the eight included CBCT studies, seven investigated the 3-dimensional effects of FAs on the upper airway in orthodontic patients. They unanimously showed these appliances result in a greater increase in upper airway volume compared with controls however, there were mixed results on the effects of FA on airway constriction (Fig. 3) (18-24).

Airway constriction

Airway constriction can be measured using either the antero-posterior (A-P) or the minimum cross-sectional area (MCA) methods. The A-P method uses several linear measurements at standardized points along the airway. It is a 2-dimensional measurement and therefore commonly used in cephalometric studies. The MCA method measures airway constriction in all CBCT slices between upper and lower boundaries. It is a three-dimensional method which cannot be used in lateral cephalometric radiographs.

Four of the studies (19,21,23,24) used MCA to assess airway constriction compared with a control group and found a significant positive effect associated with FA. Two studies (20,22) did not report on changes in airway constriction. One additional study (18) used linear A-P measurements at three standardized points along the airway and found no significant effect on airway constriction in the FA group compared with controls.

The difference in findings is likely due to the significant limitation of measuring airway constriction using a small number of linear measurements, compared with the MCA method, which measures airway constriction in all CBCT slices between upper and lower boundaries. A cephalometric study (25) measuring five A-P linear airway measurements found not all points showed improvements in the airway constriction after FA.

Another possible explanation is the study (18) had almost a 4 year mean time interval between the two scans. This raises

the possibility that any change in airway constriction because of FA treatment may be a transient effect. This explanation is less likely as several cephalometric studies, using A-P linear measurements and long-term follow-up, have shown that the enlargement of the A-P upper airway dimensions as a result of FA were maintained and stable (26-28).

Obstructive sleep apnoea

The eighth included CBCT study (29) assessed the effects of FA in children with OSA compared to an untreated OSA control group. Although a significant effect in the upper airway was found, all the airway measurements were conducted in 2-dimensions using cephalometric measurements. This was despite 3-dimensional data being available for analysis, which was a significant limitation. However, the study showed that FA use in OSA children resulted in a significant reduction in the Apnoea-Hypopnea Index (AHI) post-treatment compared with the control group. This is a significant finding and suggests correction of mandibular retrognathia using FAs during childhood may help to eliminate OSA in children, thus preventing the disease continuing into adulthood.

RME appliances

RME is a commonly used to correct transverse dental and skeletal discrepancies, while also providing an increase in arch width to resolve mild to moderate crowding (2). Force is exerted laterally against the posterior teeth or palatal mucosa which in turn places force on the mid-palatal suture. As suture is usually patent in children and adolescents, application of a force perpendicular to it leads to transverse maxillary growth (30).

Of the five included studies, four (31-34) found RME had no effects on the upper airway volume or dimensions when compared to controls (Fig. 4). The fifth study (35) found RME had a positive effect on airway volume and reduced nasal airway

clinical relevance

A narrowing of the upper airway affects the development of both the jaws and dentition in children and is consequently of interest to dentists and orthodontists. Orthodontic appliances designed to elicit skeletal changes in children may potentially cause changes in the upper airway and it is important clinicians are aware of these possible effects.

resistance. In contrast to the other studies, this study included the nasal and naso-pharyngeal airway in the volume measurements. Consequently, this suggests that, when the nasal airway and paranasal sinuses are studied in isolation, RME may have an effect on increasing the nasal airway volume and reducing the airway resistance by increasing the width of the nasal floor.

An explanation why RME has no effect on the pharyngeal airway compared with controls may be the compensatory mechanism of the head posture due to obstruction of the nasal and/or the pharyngeal airway (36). In response to airway constriction, a compensatory extension of the head in relation to the upper cervical spine (increase in the cranio-cervical angle) occurs, in order to maintain an adequate airway volume (37). It is therefore possible that RME increases the airway volume and reduces airway constriction, but the corresponding reduction in compensatory head posture leads to no overall significant net gain in airway dimensions.

Class III correction appliance

Class III skeletal relationships can be caused by maxillary retrognathia, mandibular prognathism, or a combination of ▶

FA airway effects

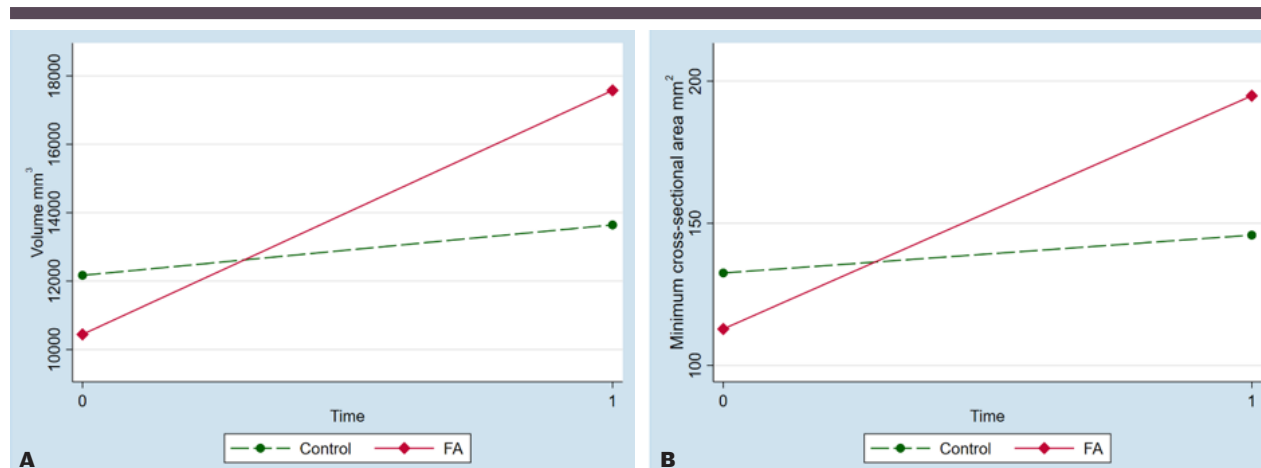


Fig. 3. Example of change in airway (A) volume and (B) MCA over time for the FA and control groups (Modified from a previously published paper) (24).

Fig. 3. Et eksempel på ændringer i (A) luftvejsvolumen og (B) MCA over tid for FA og kontrolgruppen. (Modificeret fra tidligere publiceret undersøgelse) (24).

RME airway effects

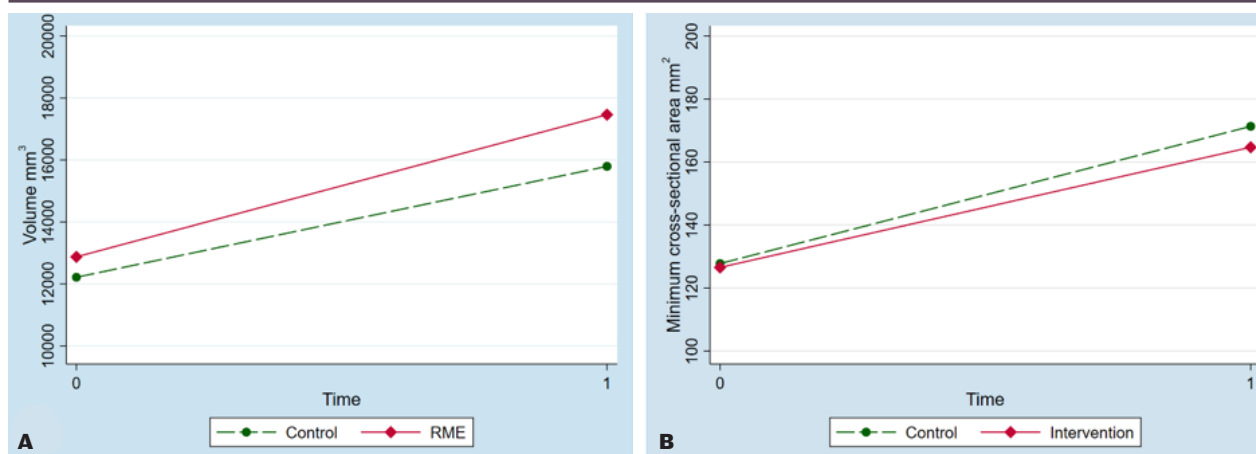


Fig. 4. Examples of change in airway (A) volume and (B) MCA over time for the RME and control groups (Modified from a previously published paper) (34).

Fig. 4. Et eksempel på ændringer i (A) luftvejsvolumen og (B) MCA over tid for RME og kontrolgruppen. (Modificeret efter en tidligere publiceret undersøgelse) (34).

both (38). Class III correction appliances are used to apply traction to advance the maxilla in children or adolescents who have maxillary retrognathia or restrict mandibular growth in patients with mandibular prognathism (39). Common treatments for maxillary retrognathia include reverse pull headgear (facemask) and bone plates. Treatment for mandibular prognathism includes chin cup therapy (39).

Three studies were identified. Two studies (38,40) used reverse pull headgear (facemask) therapy and the third used bone plates with elastic traction (39). The bone plate study compared patient airways pre- and post-treatment and found a statistically significant positive change in upper airway volume and constriction. Only the post-treatment scans were matched with an untreated class III control group and no significant difference in the airway was found between the two groups. It is difficult to draw conclusions from this study as the treatment group's data was longitudinal and the control group's data was cross-sectional in nature.

One of the reverse pull headgear studies (38) found a significant positive effect on airway volume and constriction compared with an untreated class III control group. The other study (40) found no significant airway effects, however this study used a reverse pull headgear with high forces (800 g) as the intervention group and a low force (400 g) control group, with no untreated control group.

Orthodontic extractions

The most common indications for extractions in orthodontics are excessive crowding or anteroposterior discrepancies requiring orthodontic camouflage (41). There have historically been some concerns that orthodontic extraction of permanent teeth results in a reduced arch length, therefore depriving the tongue of space and causing an impingement on the upper airway (41).

Two included studies (41,42) compared pre- and post-treatment airway volume in patients who had orthodontic treatment with and without extractions. In both studies the extraction and non-extraction groups both received treatment with fixed appliances only and were matched for molar relationship, age and gender. One study (42) also matched patients for ethnicity, pre-treatment airway volume, body mass index and height. Both studies found no significant differences in airway dimensions and volume between the extraction and non-extraction groups.

Limitations of the existing literature

Almost half the suitable studies found in the literature search had to be excluded due to the absence of a control group, and this was a particular problem in studies of RME. As there is a general increase in airway dimensions with growth in untreated children (43,44), this is a fundamental flaw in study design. Future studies need to ensure normal growth changes in the airway are accounted for with use of an appropriate age-matched control group.

The control group also needs to account for the pubertal growth spurt, when airway growth is accelerated (45). Chronological age is a poor indicator of the timing of this growth spurt, with skeletal age being a much more accurate indicator (46). Likewise, gender influences the timing of the growth spurt (46). An increased vertical jaw relationship is also associated with a narrower upper airway and a reduced skeletal response with functional appliances (47). Only one RME (34) and one FA (24) study controlled for all these variables.

There is heterogeneity among CBCT studies in measuring and defining the margins of the upper airway, making meaningful comparisons difficult. A validated method has recently been proposed (48) however, only two CBCT studies utilized

a validated method (24,34). There is also some evidence that airway measurements differ depending on the software used to measure the airway in 3-dimensions (49).

CONCLUSION

FA are associated with a significant improvement in upper airway volume and constriction when used in children. There is also some evidence that using FA in children with obstructive sleep apnoea and mandibular retrognathia may eliminate

symptoms and prevent the disease continuing into adulthood. Despite increasing inter-molar and maxillary widths, RME is not associated with a significant change in the upper airway when compared to controls, although there may be significant positive effects on the nasal and nasopharyngeal airway in isolation. There is limited evidence that reverse pull headgear (facemask) may have a positive effect on the upper airway volume. Orthodontic extractions do not appear to have negative effects on the airway. ♦

ABSTRACT (DANISH)

VIRKNINGER AF ORTODONTISK BEHANDLING PÅ ØVRE LUFTVEJE Hos BØRN

FORMÅL - At evaluere de tredimensionelle virkninger af ortodontisk behandling på luftvejene hos børn ved hjælp af cone beam computed tomography (CBCT).

METODE - En litteraturgennemgang ved hjælp af flere databaser (PubMed, Scopus, Embase, Web of Science). Den elektroniske søgning blev efterfulgt af manuel søgning af referencelister for at identificere eventuelle yderligere undersøgelser.

RESULTATER - Der blev fundet 18 undersøgelser, der havde anvendt CBCT til at undersøge den tredimensionelle ortodontiske behandlingseffekt på den øvre luftvej hos børn (otte funktionelt apparatur (FA); fem hurtig maksillær ekspansion

(RME); tre klasse III-behandlingsmekanisme; to ekstraktion kontra ikke-ekstraktion).

KONKLUSION - RME er ikke forbundet med en signifikant ændring i øvre luftvejsvolumen og luftvejskonstriktion, mens FA er forbundet med signifikante positive ændringer. Der er begrænset dokumentation for, at brugen af FA til børn med obstruktiv søvnapnø og mandibulær retrognati kan eliminere symptomer og forhindre sygdommen i at fortsætte ind i voksenalderen. Behandling af maksillær retrognati ved hjælp af omvendt headgear kan være forbundet med positive ændringer i den øvre luftvej. Ekstraktioner i forbindelse med ortodontisk behandling er ikke forbundet med negativ effekt på den øvre luftvej hos børn.

LITTERATUR

1. Anandarajah S, Dudhia R, Sandham A et al. Risk factors for small pharyngeal airway dimensions in preorthodontic children: A three-dimensional study. *Angle Orthod* 2017;87:138-46.
2. McNamara Jr JA. Early intervention in the transverse dimension: is it worth the effort? *Am J Orthod Dentofacial Orthop* 2002;121:572-4.
3. Carels C, van der Linden FP. Concepts on functional appliances' mode of action. *Am J Orthod Dentofacial Orthop* 1987;92:162-8.
4. Ng JH, Yow M. Oral Appliances in the Management of Obstructive Sleep Apnea. *Sleep Med Clin* 2019;14:109-18.
5. Knappe SW, Sonnesen L. Mandibular positioning techniques to improve sleep quality in patients with obstructive sleep apnea: current perspectives. *Nat Sci Sleep* 2018;10:65-72.
6. Warren DW, Spalding PM. Dentofacial morphology and breathing: a century of controversy. In: B. Melsen, eds. *Current controversies in orthodontics*. Chicago: Quintessence Publishing, 1991;45-76.
7. Doruk C, Sökücü O, Biçakçı AA et al. Comparison of nasal volume changes during rapid maxillary expansion using acoustic rhinometry and computed tomography. *Eur J Orthod* 2007;29:251-5.
8. Masoud AI, Jackson GW, Carley DW. Sleep and airway assessment: A review for dentists. *Cranio* 2017;35:206-22.
9. Gribel BF, Gribel MN, Frazão DC et al. Accuracy and reliability of craniometric measurements on lateral cephalometry and 3D measurements on CBCT scans. *Angle Orthod* 2011;81:26-35.
10. Lee W-C, Tu Y-K, Huang C-S et al. Pharyngeal airway changes following maxillary expansion or protraction: A meta-analysis. *Orthod Craniofac Res* 2018;21:4-11.
11. Xiang M, Hu B, Liu Y et al. Changes in airway dimensions following functional appliances in growing patients with skeletal class II malocclusion: A systematic review and meta-analysis. *Int J Pediatr Otorhinolaryngol* 2017;97:170-80.
12. McNamara JA. Components of class II malocclusion in children 8-10 years of age. *Angle Orthod* 1981;51:177-202.
13. Marschner JF, Harris JE. Mandibular growth and Class II treatment. *Angle Orthod* 1966;36:89-93.
14. Kyburz KS, Eliades T, Papageorgiou SN. What effect does functional appliance treatment have on the temporomandibular joint? A systematic review with meta-analysis. *Prog Orthod* 2019;20:32.
15. Bishara SE, Ziaja RR. Functional appliances: a review. *Am J Orthod Dentofacial Orthop* 1989;95:250-8.
16. Björk A. The relationships of the jaws to the cranium. In: A. Lundstrom, eds. *Introduction to Orthodontics*. New York: McGraw-Hill, 1960;104-40.
17. Lau EY, Sampson WJ, Townsend GC et al. An evaluation of maxillary and mandibular rotational responses with the Clark twin block appliance. *Aust Orthod J* 2009;25:48-58.
18. Iwasaki T, Takemoto Y, Inada E et al. Three-dimensional cone-beam computed tomography analysis of enlargement of the pharyngeal airway by the Herbst appliance. *Am J Orthod Dentofacial Orthop* 2014;146:776-85. ▶

19. Li L, Liu H, Cheng H et al. CBCT evaluation of the upper airway morphological changes in growing patients of class II division 1 malocclusion with mandibular retrusion using twin block appliance: a comparative research. *PLoS One* 2014;9:e94378.
20. Isidor S, Di Carlo G, Cornelis MA et al. Three-dimensional evaluation of changes in upper airway volume in growing skeletal Class II patients following mandibular advancement treatment with functional orthopedic appliances. *Angle Orthod* 2018;88:552-9.
21. Rizk S, Kulbersh VP, Al-Qawasmi R. Changes in the oropharyngeal airway of Class II patients treated with the mandibular anterior repositioning appliance. *Angle Orthod* 2016;86:955-61.
22. Oliveira PM, Cheib-Vilefort PL, de Pársia Gontijo H et al. Three-dimensional changes of the upper airway in patients with Class II malocclusion treated with the Herbst appliance: A cone-beam computed tomography study. *Am J Orthod Dentofac Orthop* 2020;157:205-11.
23. Elfeky H, Fayed MM. Three-dimensional effects of twin block therapy on pharyngeal airway parameters in Class II malocclusion patients. *J World Fed Orthod* 2015;4:114-9.
24. Abdalla Y, Brown L, Sonnesen L. Effects of a fixed functional appliance on the upper airway volume: a three-dimensional cone beam computed tomography study. *Am J Orthod Dentofac Orthop* 2020;158:40-9.
25. Ali B, Shaikh A, Fida M. Effect of Clark's twin-block appliance (CTB) and non-extraction fixed mechano-therapy on the pharyngeal dimensions of growing children. *Dent Press J Orthod* 2015;20:82-8.
26. Ulusoy C, Bavbek NC, Tuncer BB et al. Evaluation of airway dimensions and changes in hyoid bone position following class II functional therapy with activator. *Acta Odontol Scand* 2014;72:917-25.
27. Hänggi MP, Teuscher UM, Roos M et al. Long-term changes in pharyngeal airway dimensions following activator-headgear and fixed appliance treatment. *Eur J Orthod* 2008;30:598-605.
28. Han S, Choi YJ, Chung CJ et al. Long-term pharyngeal airway changes after bionator treatment in adolescents with skeletal Class II malocclusions. *Korean J Orthod* 2014;44:13-9.
29. Maspero C, Giannini L, Galbiati G et al. Upper airway obstruction in class II patients. Effects of Andresen activator on the anatomy of pharyngeal airway passage. *Cone beam evaluation. Stomatologija* 2015;17:124-30.
30. Işeri H, Tekkaya AE, Öztan Ö et al. Biomechanical effects of rapid maxillary expansion on the craniofacial skeleton, studied by the finite element method. *Eur J Orthod* 1998;20:347-56.
31. El H, Palomo JM. Three-dimensional evaluation of upper airway following rapid maxillary expansion: a CBCT study. *Angle Orthod* 2014;84:265-73.
32. Kabalan O, Gordon J, Heo G et al. Nasal airway changes in bone-borne and tooth-borne rapid maxillary expansion treatments. *Int Orthod* 2015;13:1-15.
33. Zhao Y, Nguyen M, Gohl E et al. Oropharyngeal airway changes after rapid palatal expansion evaluated with cone-beam computed tomography. *Am J Orthod Dentofac Orthop* 2010;137 (Supp 4):S71-78.
34. Abdalla Y, Brown L, Sonnesen L. Effects of rapid maxillary expansion on upper airway volume: A three-dimensional cone-beam computed tomography study. *Angle Orthod* 2019;89:917-23.
35. Iwasaki T, Saitoh I, Takemoto Y et al. Tongue posture improvement and pharyngeal airway enlargement as secondary effects of rapid maxillary expansion: a cone-beam computed tomography study. *Am J Orthod Dentofac Orthop*.2013;143:235-45.
36. Sonnesen L, Petersson A, Berg S et al. Pharyngeal Airway Dimensions and Head Posture in Obstructive Sleep Apnea Patients with and without Morphological Deviations in the Upper Cervical Spine. *J Oral Maxillofac Res* 2017;8:e4.
37. Solow B, Siersbæk-Nielsen S, Greve E. Airway adequacy, head posture, and craniofacial morphology. *Am J Orthod*.1984;86:214-23.
38. Chen X, Liu D, Liu J et al. Three-dimensional evaluation of the upper airway morphological changes in growing patients with skeletal class III malocclusion treated by protraction headgear and rapid palatal expansion: A comparative research. *PLoS One* 2015;10:e0135273.
39. Nguyen T, De Clerck H, Wilson M et al. Effect of Class III bone anchor treatment on airway. *Angle Orthod* 2015;85:591-6.
40. Pamporakis P, Nevzatoğlu Ş, Küçükkeleş N. Three-dimensional alterations in pharyngeal airway and maxillary sinus volumes in Class III maxillary deficiency subjects undergoing orthopedic face-mask treatment. *Angle Orthod* 2014;84:701-7.
41. Stefanovic N, El H, Chenin DL et al. Three-dimensional pharyngeal airway changes in orthodontic patients treated with and without extractions. *Orthod Craniofac Res* 2013;16:87-96.
42. Valiathan M, El H, Hans MG et al. Effects of extraction versus non-extraction treatment on oropharyngeal airway volume. *Angle Orthod* 2010;80:1068-74.
43. Schendel SA, Jacobson R, Khalessi S. Airway growth and development: a computerized 3-dimensional analysis. *J Oral Maxillofac Surg* 2012;70:2174-83.
44. Chiang CC, Jeffres MN, Miller A et al. Three-dimensional airway evaluation in 387 subjects from one university orthodontic clinic using cone beam computed tomography. *Angle Orthod* 2012;82:985-92.
45. Ronen O, Malhotra A, Pillar G. Influence of gender and age on upper-airway length during development. *Pediatrics* 2007;120:e1028-34.
46. Hägg U, Taranger J. Maturation indicators and the pubertal growth spurt. *Am J Orthod* 1982;82:299-309.
47. Zhong Z, Tang Z, Gao X et al. A comparison study of upper airway among different skeletal craniofacial patterns in nonsnoring Chinese children. *Angle Orthod* 2010;80:267-74.
48. Anandarajah S, Abdalla Y, Dudhia R et al. Proposal of new upper airway margins in children assessed by CBCT. *Dentomaxillofac Radiol* 2015;44:20140438.
49. Capenakas SPG. Oropharyngeal dimensional changes following maxillary expansion with two different appliances: a CBCT study [master's thesis]. Edmonton, AB: University of Alberta, 2019.

